

### ***COPYRIGHT NOTICE***

All rights and interests (including copyright) in the released test items are owned by the National Dental Examining Board of Canada (NDEB). Reproduction of these test items is permitted only on the specific terms set by the NDEB. Any editing or manipulation of these test items is strictly prohibited. The NDEB strictly prohibits the addition of answers, suggested answers, commentary, or any other additional material to these released test items. The NDEB also strictly prohibits the sale of these released test items and the distribution or sale of any material with the intent to provide the answers to the released test items. Please contact the NDEB by email at [info@ndeb-bned.ca](mailto:info@ndeb-bned.ca), or by telephone at 613-236-5912, to request written permission before reproducing the released test items.

### ***DISCLAIMER***

Since 2009, the NDEB has made available a Released Test Item Bank that includes both retired and active test items in English and French. The proportion of test item categories within the bank is not necessarily representative of the OSCE Examination Blueprints. Furthermore, the content of the released test items is not necessarily representative of any given form of past assessments or examinations.

Some of the items in the bank may have been discontinued due to outdated science or errors. In addition, some question formats may not be currently used. The NDEB periodically reviews the bank to improve its quality, content, and translation.

## QUESTION # – (MORNING/AFTERNOON) SESSION

*Using the case history and the image, answer the following question on the answer sheet.*

**Patient Information:**

Age:		Blood Pressure:	/ mmHg
Gender:		Heart Rate:	bpm
Height:	cm	Respiration Rate:	/min
Weight:	kg	Temperature:	°C

**Chief Complaint:**

**History of Chief Complaint:**

**Dental History:**

**Medical History:**

Significant Findings:  
Current Medication:  
Allergies:


**Social/Family History:**

Significant Findings:

**Clinical Examination:**

Significant Findings:  
Extraoral:  
Intraoral:

**QUESTION # – (MORNING/AFTERNOON) SESSION**



(Select **ONE** correct answer.)

Which of the following is the most likely anatomical structure/diagnosis for the entity indicated by the arrow(s)?

- A. Normal tooth.
- B. Calcifying tooth crown.
- C. Developing root apex.
- D. Hypercementosis.
- E. Attrition.
- F. Tooth fracture.
- G. Rarefying osteitis/periradicular periodontitis.
- H. Periapical cemento-osseous dysplasia.
- I. Odontoma.
- J. Dens invaginatus/dens-in-dente.
- K. Dentin dysplasia.
- L. Dentinogenesis imperfecta.
- M. Amelogenesis imperfecta.
- N. Enamel hypoplasia/Turner's tooth.
- O. Regional odontodysplasia.

## QUESTION # – (MORNING/AFTERNOON) SESSION

*Using the case history and the image, answer the following question on the answer sheet.*

**Patient Information:**

Age:		Blood Pressure:	/ mmHg
Gender:		Heart Rate:	bpm
Height:	cm	Respiration Rate:	/min
Weight:	kg	Temperature:	°C

**Chief Complaint:**

**History of Chief Complaint:**

**Dental History:**

**Medical History:**

Significant Findings:  
Current Medication:  
Allergies:

**Social/Family History:**

Significant Findings:

**Clinical Examination:**

Significant Findings:  
Extraoral:  
Intraoral:

## QUESTION # – (MORNING/AFTERNOON) SESSION



(Select **ONE** correct answer.)

Which of the following is the most likely anatomical structure/diagnosis for the radiographic entity indicated by the arrow(s)?

- A. Calcifying tooth crown.
- B. Maxillary sinus.
- C. Pterygomaxillary fissure.
- D. Ghost image.
- E. Focal osteoporotic bone marrow defect.
- F. Post-extraction socket.
- G. Odontoma.
- H. Rarefying osteitis/periradicular periodontitis.
- I. Periapical cemento-osseous dysplasia.
- J. Osteomyelitis.
- K. Keratocystic odontogenic tumour (odontogenic keratocyst).
- L. Cementoblastoma.
- M. Adenomatoid odontogenic tumour.
- N. Sialolith.
- O. Malignancy.

## QUESTION # – (MORNING/AFTERNOON) SESSION

Using the case history and the image, answer the following question on the answer sheet.

**Patient Information:**

Age:		Blood Pressure:	/ mmHg
Gender:		Heart Rate:	bpm
Height:	cm	Respiration Rate:	/min
Weight:	kg	Temperature:	°C

**Chief Complaint:**

**History of Chief Complaint:**

**Dental History:**

**Medical History:**

Significant Findings:  
Current Medication:  
Allergies:


**Social/Family History:**

Significant Findings:

**Clinical Examination:**

Significant Findings:  
Extraoral:  
Intraoral:

**QUESTION # – (MORNING/AFTERNOON) SESSION**



(Select **ONE** correct answer.)

Which of the following is the most likely anatomical structure/diagnosis for the radiographic entity indicated by the arrow(s)?

- A. Mental foramen.
- B. Mandibular foramen.
- C. Mandibular canal.
- D. Submandibular salivary gland fossa.
- E. Nutrient canal.
- F. Stafne bone defect/static bone cavity.
- G. Postsurgical defect/scar.
- H. Rarefying osteitis.
- I. Nasopalatine duct/incisive canal cyst.
- J. Simple bone cyst/traumatic bone cyst.
- K. Dentigerous/follicular cyst.
- L. Residual cyst.
- M. Lateral periodontal cyst.
- N. Periapical cemento-osseous dysplasia.
- O. Malignancy.

## QUESTION # – (MORNING/AFTERNOON) SESSION

*Using the case history and the image, answer the following question on the answer sheet.*

**Patient Information:**

Age:		Blood Pressure:	/ mmHg
Gender:		Heart Rate:	bpm
Height:	cm	Respiration Rate:	/min
Weight:	kg	Temperature:	°C

**Chief Complaint:**

**History of Chief Complaint:**

**Dental History:**

**Medical History:**

Significant Findings:  
Current Medication:  
Allergies:

**Social/Family History:**


Significant Findings:

**Clinical Examination:**

Significant Findings:  
Extraoral:  
Intraoral:



**QUESTION # – (MORNING/AFTERNOON) SESSION**



(Select **ONE** correct answer.)

Which of the following is the most likely anatomical structure/diagnosis for the radiographic entity indicated by the arrow(s)?

- A. Developing root apex.
- B. Canine fossa.
- C. Nutrient canal.
- D. Maxillary sinus.
- E. Mental foramen.
- F. Focal osteoporotic bone marrow defect.
- G. Nasopalatine foramen.
- H. Nasopalatine duct/incisive canal cyst.
- I. Rarefying osteitis.
- J. Periapical cemento-osseous dysplasia.
- K. Residual cyst.
- L. Lateral periodontal cyst.
- M. Simple bone cyst/traumatic bone cyst.
- N. Ameloblastoma.
- O. Malignancy.

## QUESTION # – (MORNING/AFTERNOON) SESSION

*Using the case history and the image, answer the following question on the answer sheet.*

**Patient Information:**

Age:		Blood Pressure:	/ mmHg
Gender:		Heart Rate:	bpm
Height:	cm	Respiration Rate:	/min
Weight:	kg	Temperature:	°C

**Chief Complaint:**

**History of Chief Complaint:**

**Dental History:**

**Medical History:**

Significant Findings:  
Current Medication:  
Allergies:


**Social/Family History:**

Significant Findings:

**Clinical Examination:**

Significant Findings:  
Extraoral:  
Intraoral:

**QUESTION # – (MORNING/AFTERNOON) SESSION**



(Select **ONE** correct answer.)

Which of the following is the most likely diagnosis?

- A. No abnormalities present.
- B. Stafne bone defect/static bone cavity.
- C. Antral pseudocyst.
- D. Soft tissue calcification.
- E. Fibro-osseous lesion/bone dysplasia.
- F. Nonodontogenic cyst.
- G. Odontogenic cyst.
- H. Benign odontogenic tumour.
- I. Osteomyelitis.
- J. Malignant neoplasm.

## QUESTION # – (MORNING/AFTERNOON) SESSION

Using the case history and the image, answer the following question on the answer sheet.

### Patient Information:

Age:		Blood Pressure:	/ mmHg
Gender:		Heart Rate:	bpm
Height:	cm	Respiration Rate:	/min
Weight:	kg	Temperature:	°C

### Chief Complaint:

### History of Chief Complaint:

### Dental History:

### Medical History:

Significant Findings:  
Current Medication:  
Allergies:

### Social/Family History:

Significant Findings:

### Clinical Examination:

Significant Findings:  
Extraoral:  
Intraoral:

**QUESTION # – (MORNING/AFTERNOON) SESSION**



(Select **ONE** correct answer.)

Which of the following is the most likely anatomical structure/diagnosis for the radiographic entity indicated by the arrow(s)?

- A. Hyoid bone.
- B. Antral septum.
- C. Soft palate.
- D. Cervical spine.
- E. Inferior concha.
- F. Tongue.
- G. Idiopathic osteosclerosis/dense bone island.
- H. Supernumerary tooth.
- I. Calcified lymph nodes.
- J. Calcified stylohyoid ligament.
- K. Maxillary sinus retention cyst/antral pseudocyst.
- L. Foreign body.
- M. Fibro-osseous lesion.
- N. Sclerosing osteitis.
- O. Malignancy.

## QUESTION # – (MORNING/AFTERNOON) SESSION

*Using the case history and the image, answer the following question on the answer sheet.*

**Patient Information:**

Age:		Blood Pressure:	/ mmHg
Gender:		Heart Rate:	bpm
Height:	cm	Respiration Rate:	/min
Weight:	kg	Temperature:	°C

**Chief Complaint:**

**History of Chief Complaint:**

**Dental History:**

**Medical History:**

Significant Findings:  
Current Medication:  
Allergies:


**Social/Family History:**

Significant Findings:

**Clinical Examination:**

Significant Findings:  
Extraoral:  
Intraoral:

**QUESTION # – (MORNING/AFTERNOON) SESSION**



(Select **ONE** correct answer.)

Which of the following is the most likely anatomical structure/diagnosis for the radiographic entity indicated by the arrow(s)?

- A. Nose.
- B. Nasal septum.
- C. Hamular process.
- D. Coronoid process.
- E. Zygomatic arch.
- F. Mylohyoid ridge.
- G. External oblique ridge.
- H. Torus.
- I. Retained root.
- J. Sclerosing osteitis.
- K. Idiopathic osteosclerosis/dense bone island.
- L. Periapical cemento-osseous dysplasia.
- M. Fibrous dysplasia.
- N. Maxillary sinus retention cyst/antral pseudocyst.
- O. Malignancy.

## QUESTION # – (MORNING/AFTERNOON) SESSION

Using the case history and the image(s), answer the following question on the answer sheet.

### Patient Information:

Age:		Blood Pressure:	/ mmHg
Gender:		Heart Rate:	bpm
Height:	cm	Respiration Rate:	/min
Weight:	kg	Temperature:	°C

### Chief Complaint:

### History of Chief Complaint:

### Dental History:

### Medical History:

Significant Findings:  
Current Medication:  
Allergies:

### Social/Family History:

Significant Findings:

### Clinical Examination:

Significant Findings:  
Extraoral:  
Intraoral:



**QUESTION # – (MORNING/AFTERNOON) SESSION**



(Select **ONE** correct answer.)

Which of the following is the most likely diagnosis for the entity shown in the image(s)?

- A. Linea alba.
- B. Fordyce granules.
- C. Leukoedema.
- D. Leukoplakia/hyperkeratosis with or without dysplasia.
- E. Frictional/traumatic keratosis.
- F. Mucosal burn.
- G. Lichen planus.
- H. Candidiasis.
- I. Hairy leukoplakia.
- J. Lupus erythematosus.
- K. White sponge nevus.
- L. Erythema migrans/geographic tongue.
- M. Hairy tongue.
- N. Verrucous carcinoma.

## QUESTION # – (MORNING/AFTERNOON) SESSION

*Using the case history and the image, answer the following question on the answer sheet.*

**Patient Information:**

Age:		Blood Pressure:	/ mmHg
Gender:		Heart Rate:	bpm
Height:	cm	Respiration Rate:	/min
Weight:	kg	Temperature:	°C

**Chief Complaint:**

**History of Chief Complaint:**

**Dental History:**

**Medical History:**

Significant Findings:  
Current Medication:  
Allergies:

**Social/Family History:**

Significant Findings:

**Clinical Examination:**

Significant Findings:  
Extraoral:  
Intraoral:

**QUESTION # – (MORNING/AFTERNOON) SESSION**



(Select **ONE** correct answer.)

Which of the following is the most likely diagnosis for the entity shown in the image(s)?

- A. No visible lesion.
- B. Aphthous ulcer(s).
- C. Herpes zoster.
- D. Traumatic ulcer(s).
- E. Recurrent herpes simplex.
- F. Primary herpetic gingivostomatitis.
- G. Necrotizing ulcerative gingivitis.
- H. Erythema migrans/geographic tongue.
- I. Mucosal burn.
- J. Lichen planus.
- K. Squamous cell carcinoma.
- L. Mucous membrane pemphigoid.
- M. Pemphigus vulgaris.
- N. Erythema multiforme.
- O. Lupus erythematosus.

## QUESTION # – (MORNING/AFTERNOON) SESSION

Using the case history and the image(s), answer the following question on the answer sheet.

### Patient Information:

Age:		Blood Pressure:	/ mmHg
Gender:		Heart Rate:	bpm
Height:	cm	Respiration Rate:	/min
Weight:	kg	Temperature:	°C

### Chief Complaint:

### History of Chief Complaint:

### Dental History:

### Medical History:

Significant Findings:  
Current Medication:  
Allergies:

### Social/Family History:

Significant Findings:

### Clinical Examination:

Significant Findings:  
Extraoral:  
Intraoral:

**QUESTION # – (MORNING/AFTERNOON) SESSION**



(Select **ONE** correct answer.)

Which of the following is the most likely diagnosis for the entity shown in the image(s)?

- A. Parotid duct papilla.
- B. Torus.
- C. Pyogenic granuloma.
- D. Mucocele (mucous extravasation cyst/phenomenon).
- E. Hemangioma.
- F. Fibroma/fibroepithelial polyp.
- G. Traumatic neuroma.
- H. Squamous papilloma.
- I. Salivary gland neoplasm.
- J. Granular cell tumour.
- K. Gingival cyst of the adult.
- L. Parulis/fistula.
- M. Inflammatory papillary hyperplasia.
- N. Epulis fissuratum/inflammatory fibrous hyperplasia.
- O. Squamous cell carcinoma.

## QUESTION # – (MORNING/AFTERNOON) SESSION

Using the case history and the image(s), answer the following question on the answer sheet.

### Patient Information:

Age:		Blood Pressure:	/ mmHg
Gender:		Heart Rate:	bpm
Height:	cm	Respiration Rate:	/min
Weight:	kg	Temperature:	°C

### Chief Complaint:

### History of Chief Complaint:

### Dental History:

### Medical History:

Significant Findings:  
Current Medication:  
Allergies:

### Social/Family History:

Significant Findings:

### Clinical Examination:

Significant Findings:  
Extraoral:  
Intraoral:

**QUESTION # – (MORNING/AFTERNOON) SESSION**



(Select **ONE** correct answer.)

Which of the following is the most likely diagnosis for the entity/entities shown in the image?

- A. Physiologic/racial pigmentation.
- B. Erythroplakia.
- C. Candidiasis.
- D. Smoker's melanosis.
- E. Lichen planus.
- F. Erythema migrans/geographic tongue.
- G. Kaposi's sarcoma.
- H. Hemangioma.
- I. Lupus erythematosus.
- J. Amalgam tattoo.
- K. Melanoma.
- L. Melanotic macule/nevus.
- M. Mucocele (mucous extravasation cyst/phenomenon).
- N. Varicosity/Varicosities.

## QUESTION # – (MORNING/AFTERNOON) SESSION

Using the case history and the image, answer the following question on the answer sheet.

### Patient Information:

Age:		Blood Pressure:	/ mmHg
Gender:		Heart Rate:	bpm
Height:	cm	Respiration Rate:	/min
Weight:	kg	Temperature:	°C

### Chief Complaint:

### History of Chief Complaint:

### Dental History:

### Medical History:

Significant Findings:  
Current Medication:  
Allergies:

### Social/Family History:

Significant Findings:

### Clinical Examination:

Significant Findings:  
Extraoral:  
Intraoral:



**QUESTION # – (MORNING/AFTERNOON) SESSION**



(Select **ONE OR MORE** correct answers.)

Which of the following is/are indicated for the **initial management** of this patient?

- A. No treatment.
- B. Topical antimicrobial.
- C. Systemic antimicrobial.
- D. Topical corticosteroid.
- E. Systemic corticosteroid.
- F. Topical anesthetic.
- G. Systemic analgesic.
- H. Protective dressing.
- I. Eliminate etiologic factor(s).
- J. Debridement.
- K. Incisional biopsy.
- L. Excisional biopsy.

## QUESTION # – (MORNING/AFTERNOON) SESSION

*Using the case history and the image, answer the following question on the answer sheet.*

**Patient Information:**

Age:		Blood Pressure:	/ mmHg
Gender:		Heart Rate:	bpm
Height:	cm	Respiration Rate:	/min
Weight:	kg	Temperature:	°C

**Chief Complaint:**

**History of Chief Complaint:**

**Dental History:**

**Medical History:**

Significant Findings:  
Current Medication:  
Allergies:

**Social/Family History:**

Significant Findings:

**Clinical Examination:**

Significant Findings:  
Extraoral:  
Intraoral:

**QUESTION # – (MORNING/AFTERNOON) SESSION**



(Select **ONE OR MORE** correct answers.)

Which of the following is/are appropriate in a **differential diagnosis** for the entity shown in the image?

- A. Normal tongue.
- B. Lingual tonsil/foliate papillae.
- C. Fissured tongue.
- D. Frictional/traumatic keratosis.
- E. Traumatic ulcer.
- F. Leukoplakia/hyperkeratosis with or without dysplasia.
- G. Hairy leukoplakia.
- H. Hairy tongue.
- I. Erythema migrans/geographic tongue.
- J. Median rhomboid glossitis.
- K. Candidiasis.
- L. Lichen planus.
- M. Squamous papilloma.
- N. Granular cell tumour.
- O. Squamous cell carcinoma.

## QUESTION # – (MORNING/AFTERNOON) SESSION

*Using the case history and the image, answer the following question on the answer sheet.*

**Patient Information:**

Age:		Blood Pressure:	/ mmHg
Gender:		Heart Rate:	bpm
Height:	cm	Respiration Rate:	/min
Weight:	kg	Temperature:	°C

**Chief Complaint:**

**History of Chief Complaint:**

**Dental History:**

**Medical History:**

Significant Findings:  
Current Medication:  
Allergies:

**Social/Family History:**

Significant Findings:

**Clinical Examination:**

Significant Findings:  
Extraoral:  
Intraoral:

**QUESTION # – (MORNING/AFTERNOON) SESSION**



(Select **ONE OR MORE** correct answers.)

Which of the following is/are appropriate in a **differential diagnosis** for the entity shown in the image?

- A. Normal buccal mucosa.
- B. Parotid duct papilla.
- C. Leukoedema.
- D. Fordyce granules.
- E. Linea alba.
- F. Frictional/traumatic keratosis.
- G. Leukoplakia/hyperkeratosis with or without dysplasia.
- H. Lichen planus.
- I. Lupus erythematosus.
- J. Mucosal burn.
- K. Aphthous ulcer.
- L. Traumatic ulcer.
- M. Traumatic purpura/ecchymosis.
- N. Fibroma/fibroepithelial polyp.
- O. Squamous papilloma.

## QUESTION # – (MORNING/AFTERNOON) SESSION





Using the case synopsis and the images, answer the following question on the answer sheet.

### CASE SYNOPSIS:

*Brief synopsis of the situation.*

(Select **ONE** correct answer.)

Which of the following pairs of images depicts the most appropriate body **and** head position for this patient at this point in time?

- A. 
- B. 
- C. 
- D. 

**QUESTION # – (MORNING/AFTERNOON) SESSION**

E.

F.

G.


H.

## QUESTION # – (MORNING/AFTERNOON) SESSION

*Using the image, answer the following question on the answer sheet.*

(Select **ONE OR MORE** correct answers.)

Which of the following locations represent the most appropriate site to check the pulse **and** the most appropriate site for chest compression in the management of a patient in cardiac arrest?



- A.
- B.
- C.
- D.
- E.
- F.
- G.
- H.
- I.
- J.



## QUESTION # – (MORNING/AFTERNOON) SESSION

*Using the case synopsis, answer the following question on the answer sheet.*

### CASE SYNOPSIS

*Brief synopsis of the situation.*

(Select **ONE OR MORE** correct answers.)

Which of the following therapeutic agents is/are appropriate as part of the management of this patient?

A.

B.

C.

D.

E.

F.

G.

H.


I.

## QUESTION # – (MORNING/AFTERNOON) SESSION

Using the case synopsis and the image(s), answer the following question on the answer sheet.

### CASE SYNOPSIS

Brief synopsis of the situation.



(Select **ONE** correct answer.)

Which of the following is the most likely diagnosis?


- A. Acute asthmatic attack (bronchospasm).
- B. Upper airway obstruction.
- C. Mild allergic reaction.
- D. Anaphylaxis.
- E. Angina pectoris/myocardial infarction.
- F. Cardiac arrest.
- G. Cerebrovascular accident.
- H. Hyperglycemia/diabetic coma.
- I. Hypoglycemia/insulin shock.
- J. Hyperventilation.
- K. Local anesthetic toxicity.
- L. Epinephrine reaction.
- M. Vasodepressor syncope.

## QUESTION # – (MORNING/AFTERNOON) SESSION

Using the case synopsis and the image(s), answer the following question on the answer sheet.

### CASE SYNOPSIS

Brief synopsis of the situation.



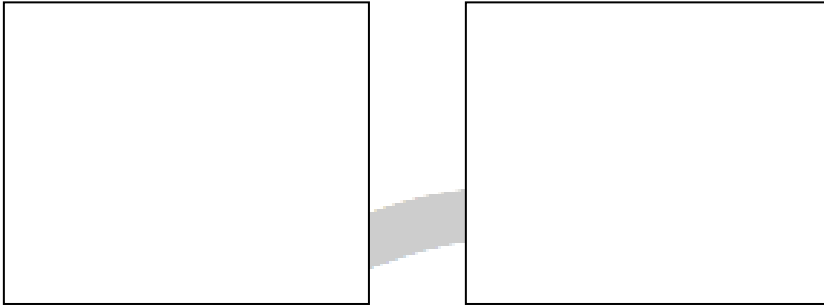
(Select **ONE OR MORE** correct answers.)

Which of the following is/are appropriate in the immediate management of this patient?

- A. No intervention necessary.
- B. Administer acetylsalicylic acid.
- C. Administer diphenhydramine.
- D. Administer epinephrine.
- E. Administer glucagon.
- F. Administer glucose orally.
- G. Administer nitroglycerin.
- H. Administer oxygen.
- I. Administer salbutamol.
- J. Head-tilt/chin-lift.
- K. Ventilate the patient and begin cardiac compressions.
- L. Abdominal thrusts.
- M. Finger sweep.
- N. Use automated external defibrillator.
- O. Call emergency medical services (911).

## QUESTION # – (MORNING/AFTERNOON) SESSION

*Using the images of the complete dentures, answer the following question on the answer sheet.*



(Select **ONE OR MORE** correct answers.)

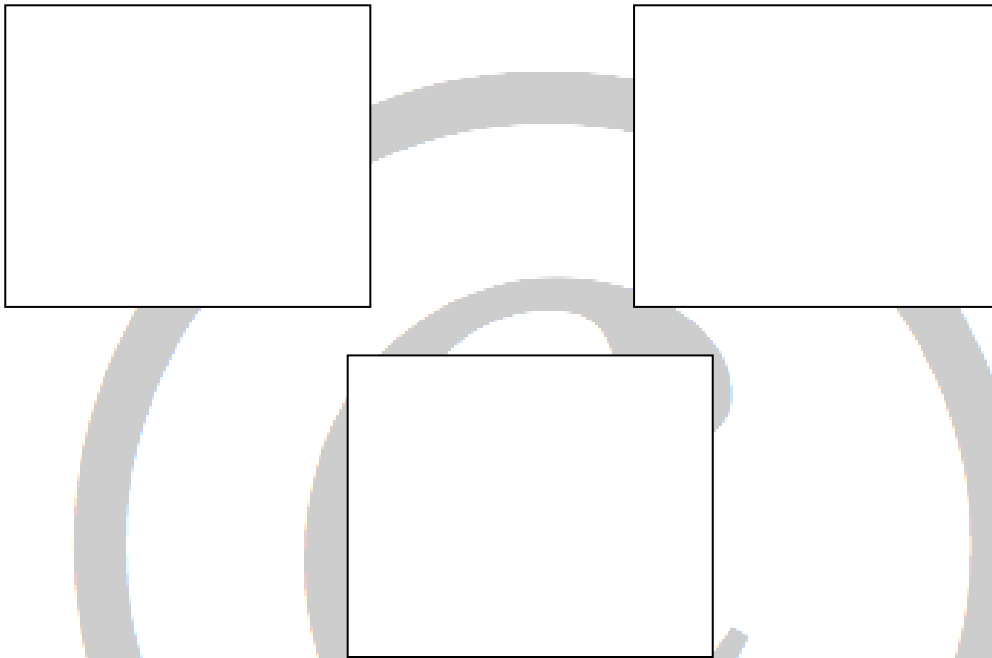
The occlusal contacts, marked in dark blue, in maximum intercuspation are

- A. acceptable.
- B. uneven in distribution in the posterior region.
- C. inappropriate in the anterior region.

**QUESTION # – (MORNING/AFTERNOON) SESSION**

**FOR PURPOSES OF THIS EXAMINATION ALL MARGINS HAVE BEEN PLACED SUPRAGINGIVALLY.**

*Using the images, answer the following question on the answer sheet.*



(Select **ONE OR MORE** correct answers.)

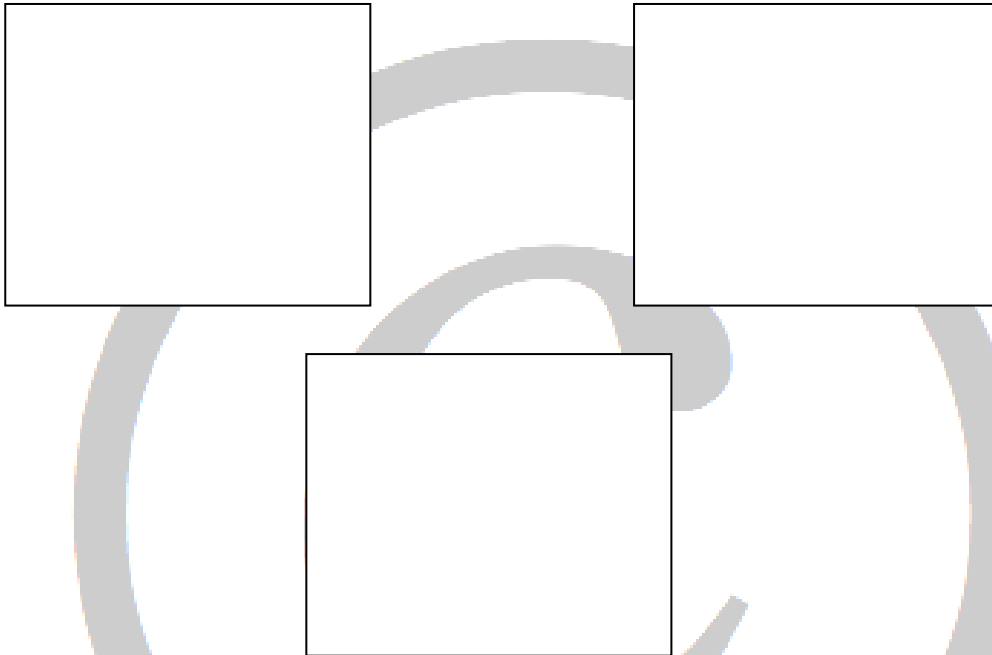
The preparation for a metal-ceramic (porcelain fused to metal) crown with metal occlusal and a buccal porcelain margin (90° butt joint) on tooth \_\_\_\_\_

- A. is acceptable.
- B. is undercut.
- C. has insufficient reduction buccally.
- D. has excessive reduction buccally.
- E. has insufficient reduction lingually.
- F. has excessive reduction lingually.
- G. has insufficient reduction mesially.
- H. has excessive reduction mesially.
- I. has insufficient reduction distally.
- J. has excessive reduction distally.
- K. has insufficient reduction occlusally.
- L. has excessive reduction occlusally.

**QUESTION # – (MORNING/AFTERNOON) SESSION**

**FOR PURPOSES OF THIS EXAMINATION ALL MARGINS HAVE BEEN PLACED SUPRAGINGIVALLY.**

*Using the images, answer the following question on the answer sheet.*



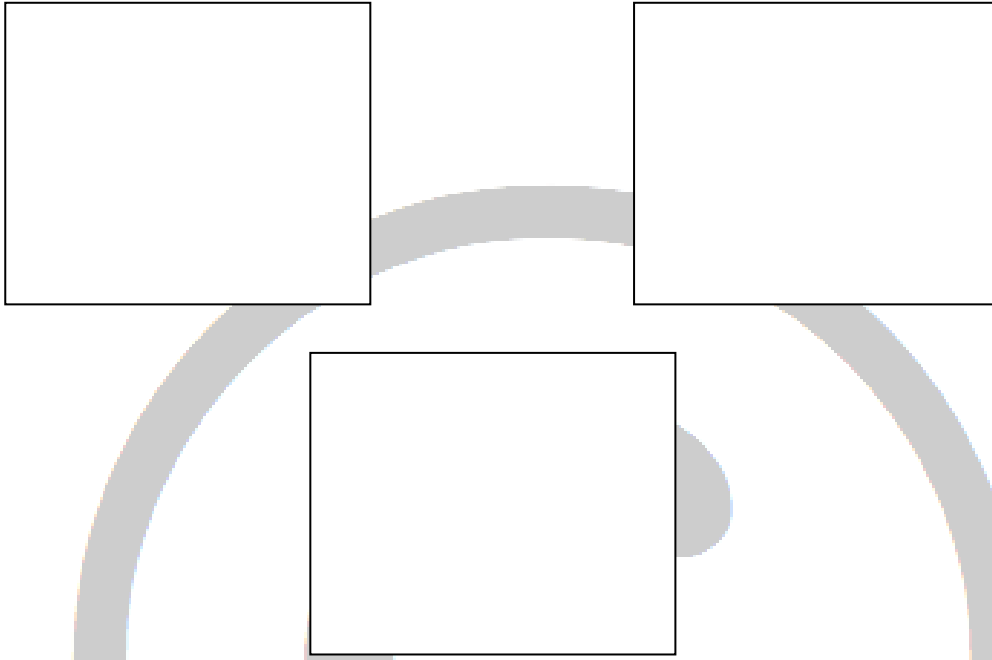
(Select **ONE OR MORE** correct answers.)

The preparation for an all-ceramic crown on tooth \_\_\_\_

- A. is acceptable.
- B. is undercut.
- C. has insufficient reduction labially/buccally.
- D. has excessive reduction labially/buccally.
- E. has insufficient reduction lingually.
- F. has excessive reduction lingually.
- G. has insufficient reduction mesially.
- H. has excessive reduction mesially.
- I. has insufficient reduction distally.
- J. has excessive reduction distally.
- K. has insufficient reduction incisally/occlusally.
- L. has excessive reduction incisally/occlusally.
- M. has unacceptably sharp angles.

## QUESTION # – (MORNING/AFTERNOON) SESSION

Using the images, answer the following question on the answer sheet.




(Select **ONE OR MORE** correct answers.)

The preparation for a full metal crown on tooth \_\_\_\_\_

- A. is acceptable.
- B. is undercut.
- C. has insufficient reduction buccally.
- D. has excessive reduction buccally.
- E. has insufficient reduction lingually.
- F. has excessive reduction lingually.
- G. has insufficient reduction mesially.
- H. has excessive reduction mesially.
- I. has insufficient reduction distally.
- J. has excessive reduction distally.

## QUESTION # – (MORNING/AFTERNOON) SESSION

Using the images, answer the following question on the answer sheet.



(Select **ONE OR MORE** correct answers.)

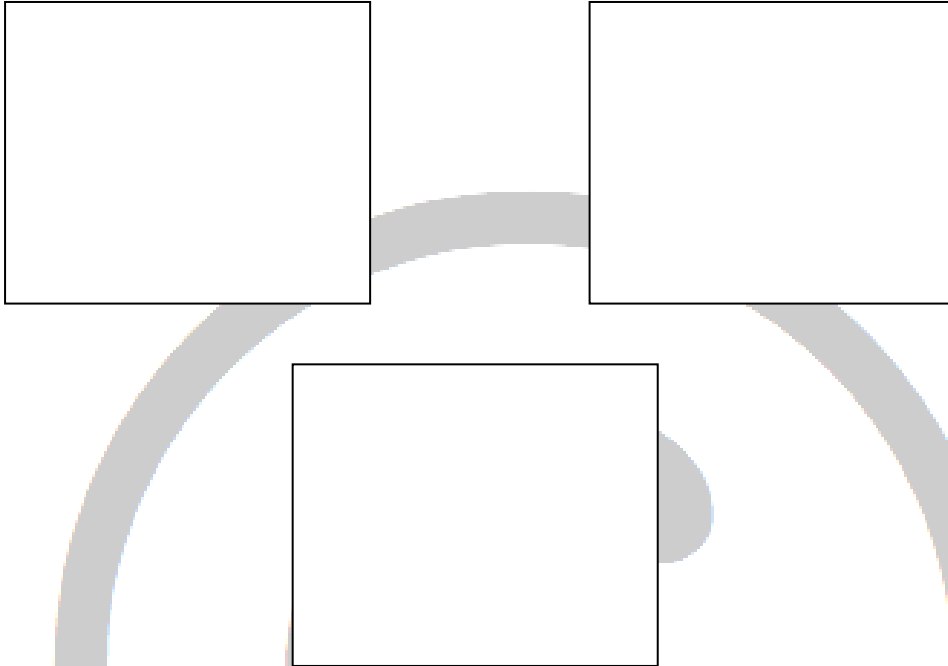
The preparation for a full metal crown on tooth \_\_\_\_ has

- A. acceptable margins.
- B. an unacceptably irregular/discontinuous margin.
- C. unsupported enamel (lipping) of the margin.
- D. excessive occlusal convergence (taper) mesiodistally.
- E. excessive occlusal convergence (taper) buccolingually.



## QUESTION # – (MORNING/AFTERNOON) SESSION

Using the images, answer the following question on the answer sheet.




(Select **ONE OR MORE** correct answers.)

The metal-ceramic (porcelain fused to metal) restoration on tooth \_\_\_\_\_

- A. is acceptable.
- B. is overcontoured on the labial/buccal.
- C. is overcontoured on the lingual.
- D. has (an) unacceptable interproximal contact(s).
- E. is too long incisally/occlusally.
- F. is too short incisally/occlusally.

## QUESTION # – (MORNING/AFTERNOON) SESSION

*Using the images, answer the following question on the answer sheet.*



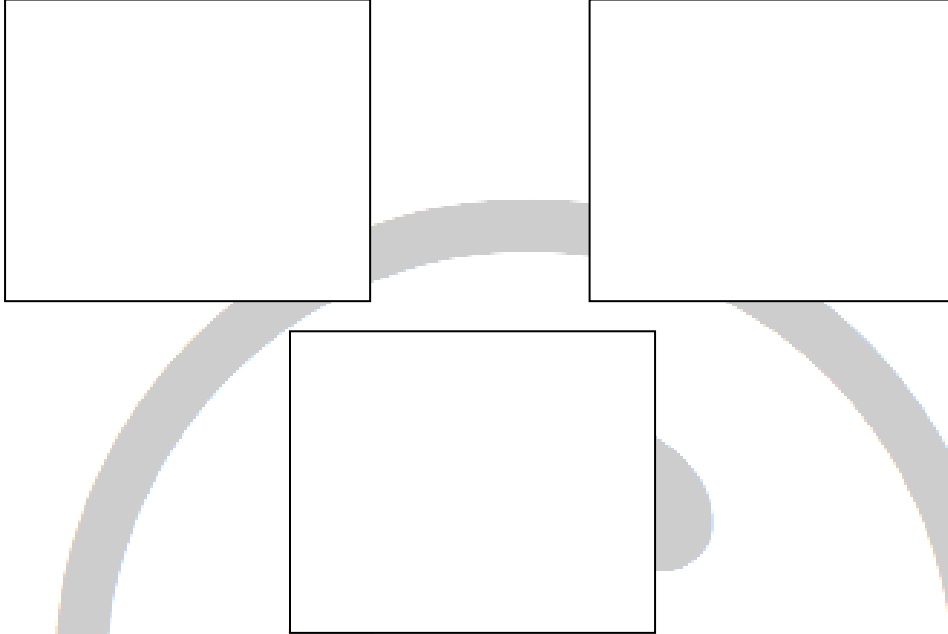
(Select **ONE OR MORE** correct answers.)

The margin on the metal-ceramic (porcelain fused to metal) restoration on tooth \_\_\_\_ is

- A. acceptable.
- B. open on the mesial.
- C. open on the distal.
- D. open on the labial/buccal.
- E. open on the lingual.
- F. overextended on the mesial.
- G. overextended on the distal.
- H. overextended on the labial/buccal.
- I. overextended on the lingual.

## QUESTION # – (MORNING/AFTERNOON) SESSION

Using the images, answer the following question on the answer sheet.





(Select **ONE OR MORE** correct answers.)

The metal-ceramic (porcelain fused to metal) restoration on tooth \_\_\_\_\_

- A. is acceptable.
- B. is overcontoured on the labial/buccal.
- C. is overcontoured on the lingual.
- D. has (an) unacceptable interproximal contact(s).
- E. is too long incisally/occlusally.
- F. is too short incisally/occlusally.
- G. is open on the mesial margin.
- H. is open on the distal margin.
- I. is open on the labial/buccal margin.
- J. is open on the lingual margin.

## QUESTION # – (MORNING/AFTERNOON) SESSION

Using the images, answer the following question on the answer sheet.




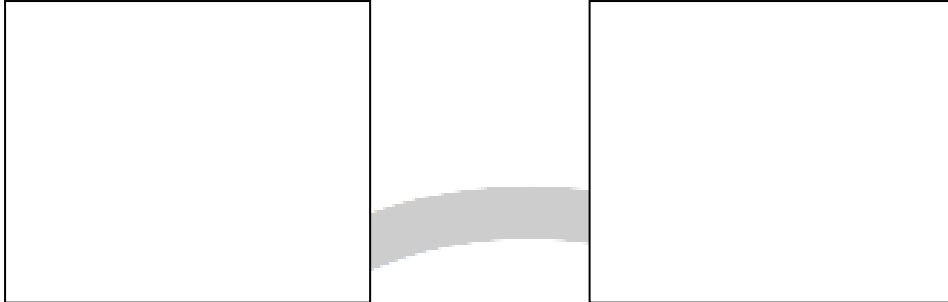
(Select **ONE OR MORE** correct answers.)

The all-ceramic restoration on tooth \_\_\_\_\_

- A. is acceptable.
- B. is overcontoured on the labial/buccal.
- C. is overcontoured on the lingual.
- D. has (an) unacceptable interproximal contact(s).
- E. is too long incisally/occlusally.
- F. is too short incisally/occlusally.

## QUESTION # – (MORNING/AFTERNOON) SESSION

*Using the images, answer the following question on the answer sheet.*



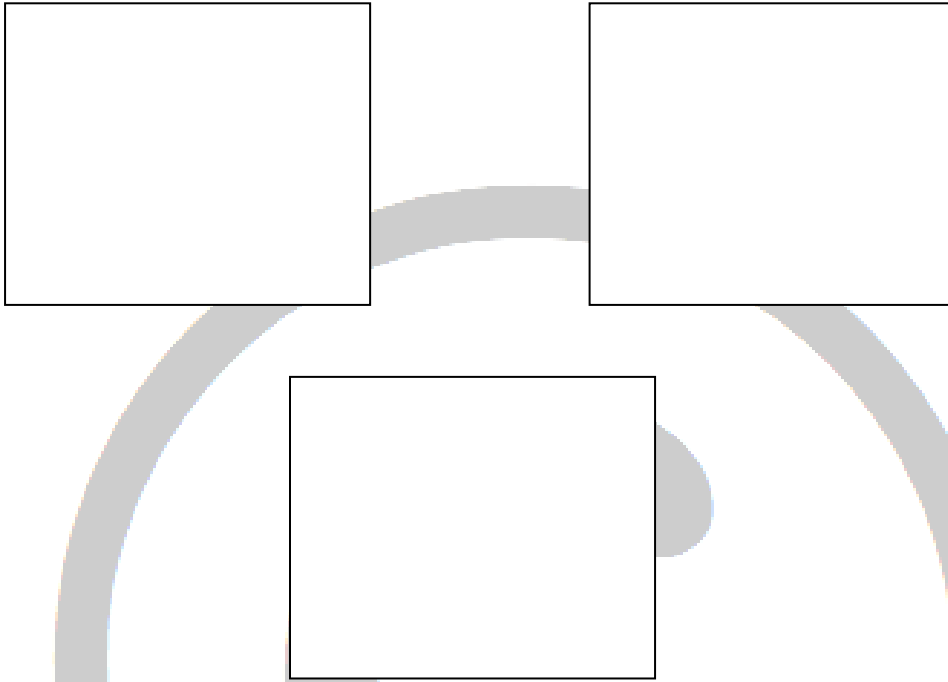
(Select **ONE OR MORE** correct answers.)

The margins on the provisional restoration on tooth \_\_\_ are

- A. acceptable.
- B. open.
- C. overcontoured.
- D. undercontoured.

## QUESTION # – (MORNING/AFTERNOON) SESSION

Using the images, answer the following question on the answer sheet.



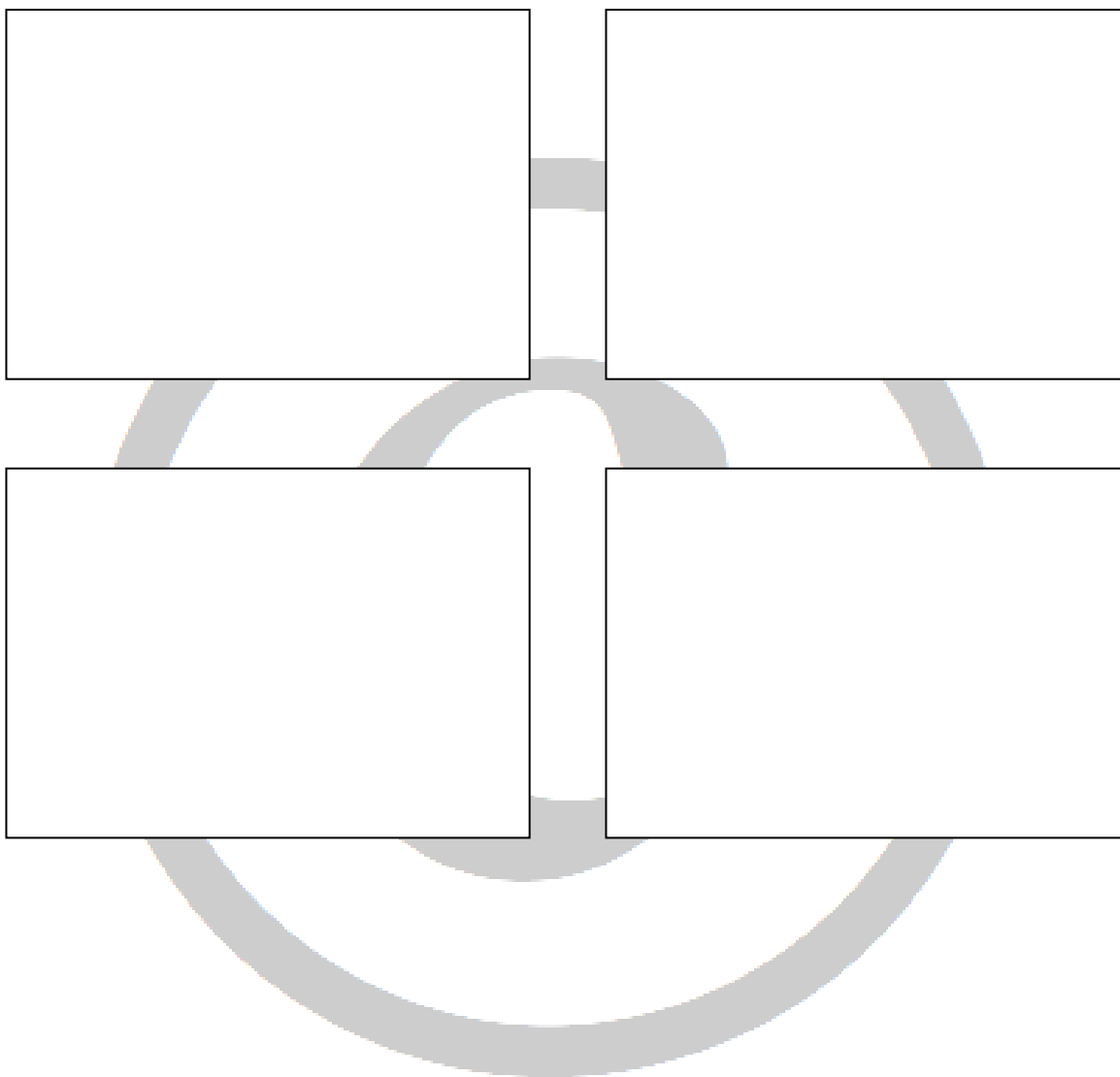
(Select **ONE OR MORE** correct answers.)

The provisional restoration on tooth \_\_\_\_




- A. has acceptable contours and contacts.
- B. has unacceptable buccal contour.
- C. has unacceptable lingual contour.
- D. has unacceptable proximal contact(s).
- E. has (a) marginal ridge discrepancy(ies).
- F. is in supraocclusion.
- G. is in infraocclusion.

## QUESTION # – (MORNING/AFTERNOON) SESSION

*Using the images, answer the following question on the answer sheet.*



**QUESTION # – (MORNING/AFTERNOON) SESSION**



(Select **ONE OR MORE** correct answers.)


Which of the following modifications is/are required to make the \_\_\_\_ preparation on tooth \_\_\_\_ acceptable for an amalgam restoration?

- A. No modifications required.
- B. Deepen the pulpal floor.
- C. Deepen the mesial axial wall.
- D. Deepen the distal axial wall.
- E. Increase the occlusal retention and resistance form.
- F. Correct the mesiobuccal wall.
- G. Correct the mesiolingual wall.
- H. Correct the distobuccal wall.
- I. Correct the distolingual wall.
- J. Extend the mesio gingival floor gingivally.
- K. Extend the disto gingival floor gingivally.
- L. Finish the cavosurface margin(s).



## QUESTION # – (MORNING/AFTERNOON) SESSION

Using the image, answer the following question on the answer sheet.





(Select **ONE OR MORE** correct answers.)

Based on the radiographic evidence, which of the following surfaces require restoration?

- A. Distal of tooth \_\_\_.
- B. Mesial of tooth \_\_\_.
- C. Distal of tooth \_\_\_.
- D. Mesial of tooth \_\_\_.
- E. Distal of tooth \_\_\_.
- F. Mesial of tooth \_\_\_.
- G. Distal of tooth \_\_\_.
- H. Mesial of tooth \_\_\_.
- I. Distal of tooth \_\_\_.
- J. Mesial of tooth \_\_\_.
- K. Distal of tooth \_\_\_.
- L. None of the above.

## QUESTION # – (MORNING/AFTERNOON) SESSION

*Using the images, answer the following question on the answer sheet.*


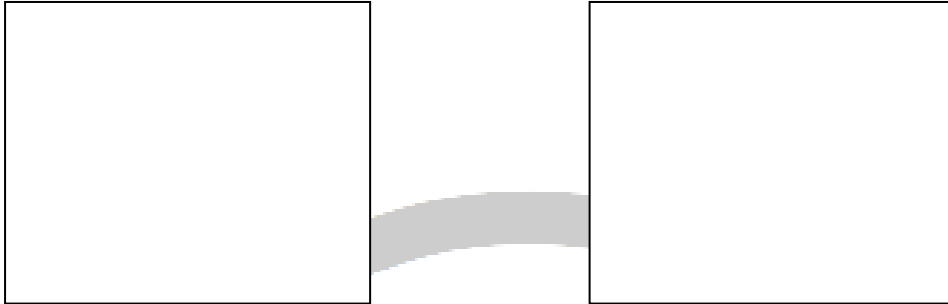


(Select **ONE OR MORE** correct answers.)  
The composite resin restoration on tooth \_\_\_\_

- A. is acceptable.
- B. is overcontoured/has excess material.
- C. is undercontoured.
- D. has (an) open interproximal contact(s).
- E. has (a) void(s).

## QUESTION # – (MORNING/AFTERNOON) SESSION

Using the images, answer the following question on the answer sheet.



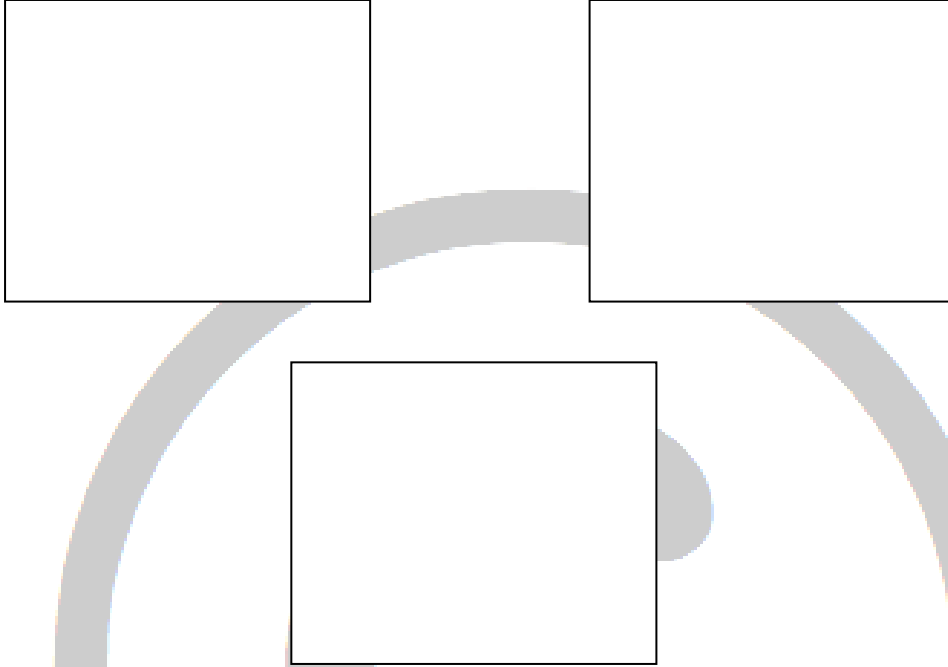
(Select **ONE OR MORE** correct answers.)

The amalgam restoration on tooth \_\_\_\_

- A. is acceptable.
- B. is overcontoured/has excess material.
- C. is undercontoured.
- D. has (an) open interproximal contact(s).
- E. has (a) void(s).

## QUESTION # – (MORNING/AFTERNOON) SESSION

Using the images, answer the following question on the answer sheet.



(Select **ONE OR MORE** correct answers.)

The MOD composite resin restoration on tooth \_\_\_\_

- A. is acceptable.
- B. is overcontoured/has excess material occlusally.
- C. is undercontoured occlusally.
- D. has an open interproximal mesial contact.
- E. has an open interproximal distal contact.
- F. has (a) void(s).
- G. has an overcontoured mesial surface.
- H. has an overcontoured distal surface.

## QUESTION # – (MORNING/AFTERNOON) SESSION

Using the images, answer the following question on the answer sheet. The age-appropriate mean as well as the patient-specific mandibular plane angle measurements are provided.



Mean Frankfort horizontal to mandibular plane = \_\_\_°  
Mean Sella-Nasion to mandibular plane = \_\_\_°

Patient's Frankfort horizontal to mandibular plane = \_\_\_°  
Patient's Sella-Nasion to mandibular plane = \_\_\_°

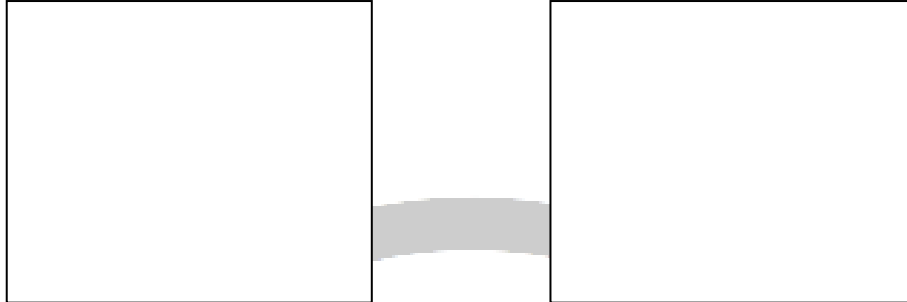
(Select **ONE** correct answer.)

The patient has a lower anterior face height

- A. that is within normal limits with a normal mandibular plane.
- B. that is within normal limits with a steep (high) mandibular plane.
- C. that is within normal limits with a flat (low) mandibular plane.
- D. shorter than normal with a normal mandibular plane.
- E. shorter than normal with a steep (high) mandibular plane.
- F. shorter than normal with a flat (low) mandibular plane.
- G. longer than normal with a normal mandibular plane.
- H. longer than normal with a steep (high) mandibular plane.
- I. longer than normal with a flat (low) mandibular plane.

## QUESTION # – (MORNING/AFTERNOON) SESSION

*Using the images, answer the following question on the answer sheet.*



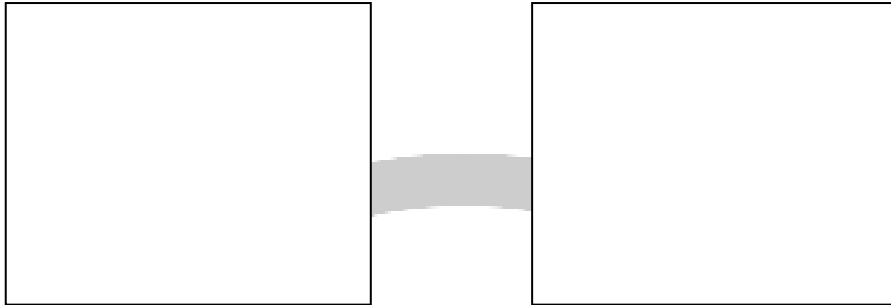
(Select **ONE** correct answer.)

Orthodontic treatment for this patient

- A. is not required at this time.
- B. should be initiated now.
- C. should be considered after reassessment in 6–9 months.
- D. should be initiated during the late mixed dentition prior to the pubertal growth spurt.
- E. should be initiated immediately following the eruption of the permanent 2<sup>nd</sup> molars.
- F. should be initiated after the completion of growth.

## QUESTION # – (MORNING/AFTERNOON) SESSION

Using the images, answer the following question on the answer sheet. The age-appropriate mean and the patient-specific SNA and SNB measurements are provided.



Mean SNA = \_\_\_\_\_° Patient's SNA = \_\_\_\_\_°  
Mean SNB = \_\_\_\_\_° Patient's SNB = \_\_\_\_\_°

(Select **ONE** correct answer.)

Based on the images and measurements provided, which of the following dental and skeletal relationships does the patient have?

- A. Angle Class I with normal skeletal relationships.
- B. Angle Class I with maxillary prognathism/protrusion.
- C. Angle Class I with maxillary retrognathism/retrusion.
- D. Angle Class I with mandibular prognathism/protrusion.
- E. Angle Class I with mandibular retrognathism/retrusion.
- F. Angle Class II with normal skeletal relationships.
- G. Angle Class II with maxillary prognathism/protrusion.
- H. Angle Class II with maxillary retrognathism/retrusion.
- I. Angle Class II with mandibular prognathism/protrusion.
- J. Angle Class II with mandibular retrognathism/retrusion.
- K. Angle Class III with normal skeletal relationships.
- L. Angle Class III with maxillary prognathism/protrusion.
- M. Angle Class III with maxillary retrognathism/retrusion.
- N. Angle Class III with mandibular prognathism/protrusion.
- O. Angle Class III with mandibular retrognathism/retrusion.

## QUESTION # – (MORNING/AFTERNOON) SESSION

**PLEASE NOTE: THERE IS ONLY ONE QUESTION AT THIS STATION**

*Using the images, answer the following question on the answer score sheet. A Moyer's Probability Table is provided.*





**Moyer's prediction values (75% level)**

<i>Total Mandibular-Incisor Width</i>		19.5	20.0	20.5	21.0	21.5	22.0	22.5	23.0	23.5	24.0
Predicted width of canine and premolars	Maxilla	20.6	20.9	21.2	21.3	21.8	22.0	22.3	22.6	22.9	23.1
	Mandible	20.1	20.4	20.7	21.0	21.3	21.6	21.9	22.2	22.5	22.8
<i>Total Mandibular-Incisor Width</i>		24.5	25.0	25.5	26.0	26.5	27.0	27.5	28.0	28.5	29.0
Predicted width of canine and premolars	Maxilla	23.4	23.7	24.0	24.2	24.5	24.8	25.0	25.3	25.6	25.9
	Mandible	23.1	23.4	23.7	24.0	24.3	24.6	24.8	25.1	25.4	25.7





**QUESTION # – (MORNING/AFTERNOON) SESSION**



(Select **ONE OR MORE** correct answers.)

In the **maxillary** arch a mixed dentition space analysis predicts that the patient will have

- A. more than 2 mm of total crowding.
- B. more than 2 mm of total spacing.
- C. between 0-2 mm of total spacing or crowding.

## QUESTION # – (MORNING/AFTERNOON) SESSION

**PLEASE NOTE: THERE IS ONLY ONE QUESTION AT THIS STATION**

*Using the images, answer the following question on the answer score sheet. A Moyer's Probability Table are provided.*




**Moyer's prediction values (75% level)**

<i>Total Mandibular-Incisor Width</i>		19.5	20.0	20.5	21.0	21.5	22.0	22.5	23.0	23.5	24.0
Predicted width of canine and premolars	Maxilla	20.6	20.9	21.2	21.3	21.8	22.0	22.3	22.6	22.9	23.1
	Mandible	20.1	20.4	20.7	21.0	21.3	21.6	21.9	22.2	22.5	22.8
<i>Total Mandibular-Incisor Width</i>		24.5	25.0	25.5	26.0	26.5	27.0	27.5	28.0	28.5	29.0
Predicted width of canine and premolars	Maxilla	23.4	23.7	24.0	24.2	24.5	24.8	25.0	25.3	25.6	25.9
	Mandible	23.1	23.4	23.7	24.0	24.3	24.6	24.8	25.1	25.4	25.7



**QUESTION # – (MORNING/AFTERNOON) SESSION**




(Select **ONE OR MORE** correct answers.)

In the **mandibular** arch a mixed dentition space analysis predicts that the patient will have

- A. more than 2 mm of total crowding.
- B. more than 2 mm of total spacing.
- C. between 0-2 mm of total spacing or crowding.

## QUESTION # – (MORNING/AFTERNOON) SESSION

Using the image(s), answer the following question on the answer sheet.




(Select **ONE** correct answer.)

Which of the following dental occlusions does the patient have?

- A. Angle Class I with a normal overbite.
- B. Angle Class II, division 1 with a normal overbite.
- C. Angle Class II, division 2 with a normal overbite.
- D. Angle Class III with a normal overbite.
- E. Angle Class I with an open bite.
- F. Angle Class II, division 1 with an open bite.
- G. Angle Class II, division 2 with an open bite.
- H. Angle Class III with an open bite.
- I. Angle Class I with a deep bite.
- J. Angle Class II, division 1 with a deep bite.
- K. Angle Class II, division 2 with a deep bite.
- L. Angle Class III with a deep bite.
- M. Mesial step terminal plane.
- N. Straight (flush) terminal plane.
- O. Distal step terminal plane.

## QUESTION # – (MORNING/AFTERNOON) SESSION

Using the image(s), answer the following question on the answer sheet.




(Select **ONE OR MORE** correct answers.)

Which of the following is/are appropriate interceptive orthodontic treatment(s) for this patient?

- A. No treatment at this time.
- B. Interproximal discing of one or more primary canines.
- C. Interproximal discing of one or more primary molars.
- D. Extraction of one or 2 primary maxillary canines.
- E. Extraction of one or 2 primary mandibular canines.
- F. Extraction of one or more primary maxillary molars.
- G. Extraction of one or more primary mandibular molars.
- H. Space maintenance in the maxillary arch.
- I. Space maintenance in the mandibular arch.
- J. Space regaining in the maxillary arch.
- K. Space regaining in the mandibular arch.
- L. Habit breaking appliance.
- M. Posterior bilateral maxillary arch expansion.
- N. Occlusal adjustment of one or more teeth.
- O. Molar disimpaction.

## QUESTION # – (MORNING/AFTERNOON) SESSION

Using the image(s), answer the following question on the answer sheet.




(Select **ONE OR MORE** correct answers.)

Which of the following is/are appropriate interceptive orthodontic treatment(s) for this patient?

- A. No treatment at this time.
- B. Interproximal discing of one or more primary canines.
- C. Interproximal discing of one or more primary molars.
- D. Extraction of one or 2 primary maxillary canines.
- E. Extraction of one or 2 primary mandibular canines.
- F. Extraction of one or more primary maxillary molars.
- G. Extraction of one or more primary mandibular molars.
- H. Space maintenance in the maxillary arch.
- I. Space maintenance in the mandibular arch.
- J. Space regaining in the maxillary arch.
- K. Space regaining in the mandibular arch.
- L. Habit breaking appliance.
- M. Posterior bilateral maxillary arch expansion incorporating habit control.
- N. Posterior bilateral maxillary arch expansion.
- O. Anterior crossbite correction.

## QUESTION # – (MORNING/AFTERNOON) SESSION

Using the image(s), answer the following question on the answer sheet.




(Select **ONE OR MORE** correct answers.)

At this time, which of the following is/are appropriate interceptive orthodontic treatment(s) for this patient?

- A. No treatment at this time.
- B. Space regaining in the maxillary arch.
- C. Space regaining in the mandibular arch.
- D. Habit breaking appliance.
- E. Posterior bilateral maxillary arch expansion incorporating habit control.
- F. Posterior bilateral maxillary arch expansion.
- G. Anterior crossbite correction.
- H. Growth modification appliance.

## QUESTION # – (MORNING/AFTERNOON) SESSION

Using the image(s), answer the following question on the answer sheet.



(Select **ONE OR MORE** correct answers.)


What is/are the appropriate treatment(s) for the spacing/crowding in the maxillary arch at this time?

- A. Wait for eruption of permanent maxillary canines and then reassess.
- B. Frenectomy.
- C. Orthodontic closure.
- D. Extraction of one or more supernumerary teeth.
- E. Extraction of one or more primary canines.
- F. Interproximal reduction (discing) of one or more primary canines.
- G. Leeway space preservation.
- H. Orthodontic treatment followed by esthetic restoration(s).
- I. Esthetic restoration(s) without orthodontic treatment.
- J. Arch expansion.
- K. Bite opening.
- L. Bite closing.



## QUESTION # – (MORNING/AFTERNOON) SESSION

Using the image(s), answer the following question on the answer sheet.




(Select **ONE OR MORE** correct answers.)

What is/are the appropriate treatment(s) for the spacing/crowding in the mandibular arch at this time?

- A. Wait for eruption of permanent mandibular canines and then reassess.
- B. Frenectomy.
- C. Orthodontic closure.
- D. Extraction of one or more supernumerary teeth.
- E. Extraction of one or more primary canines.
- F. Interproximal reduction (discing) of one or more primary canines.
- G. Leeway space preservation.
- H. Orthodontic treatment followed by esthetic restoration(s).
- I. Esthetic restoration(s) without orthodontic treatment.
- J. Arch expansion.
- K. Bite opening.
- L. Bite closing.

## QUESTION # – (MORNING/AFTERNOON) SESSION

Using the image(s), answer the following question on the answer sheet.



(Select **ONE OR MORE** correct answers.)

A comprehensive treatment plan for this patient undergoing orthodontic treatment should include

- A. frenectomy.
- B. gingival grafting.
- C. esthetic restoration.
- D. interproximal reduction (discing).
- E. third molar removal.
- F. gingivectomy.

## QUESTION # – (MORNING/AFTERNOON) SESSION

Using the image, answer the following question on the answer sheet.



(Select **ONE OR MORE** correct answers.)

Which of the following may complicate the root canal treatment on tooth \_\_\_\_\_?

- A. No complicating factors present.
- B. Presence of accessory canals/canal subdivision.
- C. Curved/atypical root morphology.
- D. Pulp stones/calcification of the pulp chamber.
- E. Calcification of root canal(s).
- F. Internal resorption.
- G. External resorption.
- H. Extensive restoration.
- I. Caries.
- J. Rotated or tipped tooth.
- K. Tooth fracture.
- L. Open apex.

## QUESTION # – (MORNING/AFTERNOON) SESSION

Using the case history and the image(s), answer the following question on the answer sheet.

### Patient Information:

Age:		Blood Pressure:	/ mmHg
Gender:		Heart Rate:	bpm
Height:	cm	Respiration Rate:	/min
Weight:	kg	Temperature:	°C

### Chief Complaint:

### History of Chief Complaint:

### Dental History:

### Medical History:

Significant Findings:  
Current Medication:  
Allergies:


### Social/Family History:

Significant Findings:

### Clinical Examination:

Significant Findings:  
Extraoral:  
Intraoral:

**QUESTION # – (MORNING/AFTERNOON) SESSION**



(Select **ONE OR MORE** correct answers.)

Which of the following describe(s) the access preparation on tooth \_\_\_\_?

- A. Access cavity is acceptable.
- B. Perforation of the furcation.
- C. Lateral perforation of the crown and/or root.
- D. Damage to pulpal wall(s).
- E. Damage to pulpal floor.
- F. Inadequate exposure of canal orifices.
- G. Inadequate pretreatment of the tooth.

## QUESTION # – (MORNING/AFTERNOON) SESSION

Using the case history and the image, answer the following question on the answer sheet.

### Patient Information:

Age:		Blood Pressure:	/ mmHg
Gender:		Heart Rate:	bpm
Height:	cm	Respiration Rate:	/min
Weight:	kg	Temperature:	°C

### Chief Complaint:

### History of Chief Complaint:

### Dental History:

### Medical History:

Significant Findings:  
Current Medication:  
Allergies:

### Social/Family History:

Significant Findings:

### Clinical Examination:

Significant Findings:  
Extraoral:  
Intraoral:

**QUESTION # – (MORNING/AFTERNOON) SESSION**



(Select **ONE OR MORE** correct answers.)

What is/are the appropriate immediate management(s) of tooth \_\_\_\_?

- A. No treatment required.
- B. Correct occlusal contacts.
- C. Retreat endodontically.
- D. Place a definitive restoration.
- E. Bleaching.
- F. Apexogenesis.
- G. Apexification.
- H. Perform apical surgery and place a retrograde filling.
- I. Perform a biopsy.
- J. Hemisection.
- K. Root amputation.
- L. Pulpotomy.
- M. Pulpectomy.
- N. Extract the tooth.

## QUESTION # – (MORNING/AFTERNOON) SESSION

Using the case history and the image, answer the following question on the answer sheet.

### Patient Information:

Age:		Blood Pressure:	/ mmHg
Gender:		Heart Rate:	bpm
Height:	cm	Respiration Rate:	/min
Weight:	kg	Temperature:	°C

### Chief Complaint:

### History of Chief Complaint:

### Dental History:

### Medical History:

Significant Findings:  
Current Medication:  
Allergies:

### Social/Family History:

Significant Findings:

### Clinical Examination:

Significant Findings:  
Extraoral:  
Intraoral:



**QUESTION # – (MORNING/AFTERNOON) SESSION**



(Select **ONE OR MORE** correct answers.)

Which of the following describes the endodontic treatment of tooth \_\_\_\_\_?

- A. Acceptable.
- B. Furcation perforation.
- C. Lateral perforation.
- D. Apical perforation/transportation.
- E. Unacceptable short fill.
- F. Inadequate compaction (voids).
- G. Overfilled/extrusion.
- H. Unacceptable shaping.
- I. Separated instrument.
- J. Inappropriate obturation material.
- K. Untreated canal.

## QUESTION # – (MORNING/AFTERNOON) SESSION

*Using the case history and the images, answer the following question on the answer sheet.*

**Patient Information:**

Age:		Blood Pressure:	/ mmHg
Gender:		Heart Rate:	bpm
Height:	cm	Respiration Rate:	/min
Weight:	kg	Temperature:	°C

**Chief Complaint:**

**History of Chief Complaint:**

**Dental History:**

**Medical History:**

Significant Findings:  
Current Medication:  
Allergies:


**Social/Family History:**

Significant Findings:

**Clinical Examination:**

Significant Findings:  
Extraoral:  
Intraoral:

**QUESTION # – (MORNING/AFTERNOON) SESSION**



(Select **ONE OR MORE** correct answers.)

Which of the following emergency managements would be most appropriate for tooth \_\_\_\_?

- A. No treatment and monitor.
- B. Pulpectomy/establish drainage through tooth.
- C. Pulpotomy.
- D. Periapical surgery.
- E. Extraction.
- F. Incision and drainage.
- G. Replant and splint.
- H. Reposition and splint.
- I. Restore.
- J. Pulp cap.
- K. Antibiotic therapy.
- L. Analgesics.
- M. Adjust occlusion.

## QUESTION # – (MORNING/AFTERNOON) SESSION

*Using the case history and the images, answer the following question on the answer sheet.*

**Patient Information:**

Age:		Blood Pressure:	/ mmHg
Gender:		Heart Rate:	bpm
Height:	cm	Respiration Rate:	/min
Weight:	kg	Temperature:	°C

**Chief Complaint:**

**History of Chief Complaint:**

**Dental History:**

**Medical History:**

Significant Findings:  
Current Medication:  
Allergies:

**Social/Family History:**

Significant Findings:

**Clinical Examination:**

Significant Findings:  
Extraoral:  
Intraoral:

## QUESTION # – (MORNING/AFTERNOON) SESSION



(Select **ONE OR MORE** correct answers.)

Which of the following is/are the most likely diagnosis/diagnoses for tooth \_\_\_\_\_?

- A. Normal pulp.
- B. Reversible pulpitis.
- C. Asymptomatic irreversible pulpitis.
- D. Symptomatic irreversible pulpitis.
- E. Pulp necrosis.
- F. Symptomatic apical periodontitis.
- G. Acute apical abscess.
- H. Asymptomatic apical periodontitis.
- I. Chronic apical abscess.
- J. Root fracture.
- K. Internal resorption.
- L. External resorption.
- M. Combined endodontic-periodontic lesion.
- N. Hyperplastic pulpitis/pulp polyp.

## QUESTION # – (MORNING/AFTERNOON) SESSION

*Using the case history and the images, answer the following question on the answer sheet.*

**Patient Information:**

Age:		Blood Pressure:	/ mmHg
Gender:		Heart Rate:	bpm
Height:	cm	Respiration Rate:	/min
Weight:	kg	Temperature:	°C

**Chief Complaint:**

**History of Chief Complaint:**

**Dental History:**

**Medical History:**

Significant Findings:  
Current Medication:  
Allergies:


**Social/Family History:**

Significant Findings:


**Clinical Examination:**

Significant Findings:  
Extraoral:  
Intraoral:

**QUESTION # – (MORNING/AFTERNOON) SESSION**



( \_\_\_ months post-op)



( \_\_\_ years post-op)

(Select **ONE OR MORE** correct answers.)

Tooth \_\_\_ demonstrates

- A. complete healing.
- B. incomplete healing.
- C. an asymptomatic apical periodontitis.
- D. a chronic apical abscess.
- E. a symptomatic apical periodontitis.
- F. an acute apical abscess.
- G. a root fracture.
- H. an inadequate coronal restoration.
- I. a furcation involvement.
- J. an inappropriate post length/diameter/space preparation.

## QUESTION # – (MORNING/AFTERNOON) SESSION

Using the image, answer the following question on the answer sheet.



(Select **ONE OR MORE** correct answers.)


Which of the following may complicate the extraction of tooth \_\_\_\_?

- A. Hypercementosis.
- B. Root morphology.
- C. Ankylosis.
- D. Extensive caries.
- E. Proximity to adjacent tooth/teeth.
- F. Increased bone density.
- G. Impacted tooth.
- H. Isolated tooth.
- I. Extensive restoration.
- J. Endodontically treated tooth.
- K. Atrophic mandible/maxilla.
- L. Proximity to mandibular canal.
- M. Proximity to maxillary sinus.
- N. Associated pathological lesion.



## QUESTION # – (MORNING/AFTERNOON) SESSION

Using the diagram, answer the following question on the answer sheet.



(Select **ONE** correct answer.)

A flap is required to remove tooth \_\_\_\_\_. Which combination of sequential points indicates the most appropriate flap?

- A. 1-2-3-4
- B. 2-3
- C. 3-2-5
- D. 1-2-3-6
- E. 1-2-3-4-6
- F. 5-3-4
- G. 1-2-6
- H. 5-2-3-6
- I. 3-6
- J. 5-2-3-4-6

## QUESTION # – (MORNING/AFTERNOON) SESSION

*Using the case history and the image(s), answer the following question on the answer sheet.*

**Patient Information:**

Age:		Blood Pressure:	/ mmHg
Gender:		Heart Rate:	bpm
Height:	cm	Respiration Rate:	/min
Weight:	kg	Temperature:	°C

**Chief Complaint:**

**History of Chief Complaint:**

**Dental History:**

**Medical History:**

Significant Findings:  
Current Medication:  
Allergies:



**Social/Family History:**

Significant Findings:

**Clinical Examination:**

Significant Findings:  
Extraoral:  
Intraoral:


**QUESTION # – (MORNING/AFTERNOON) SESSION**



(Select **ONE OR MORE** correct answers.)

If extraction of tooth \_\_\_\_\_ is performed, which of the following complications is/are likely?

- A. Coronal tooth/root fracture.
- B. Oroantral communication/fistula.
- C. Paresthesia.
- D. Alveolar bone fracture.



## QUESTION # – (MORNING/AFTERNOON) SESSION

*Using the case history and the images, answer the following question on the answer sheet.*

**Patient Information:**

Age:		Blood Pressure:	/ mmHg
Gender:		Heart Rate:	bpm
Height:	cm	Respiration Rate:	/min
Weight:	kg	Temperature:	°C

**Chief Complaint:**

**Dental History:**

**History of Chief Complaint:**

**Dental History:**

**Medical History:**

Significant Findings:  
Current Medication:  
Allergies:



**Social/Family History:**

Significant Findings:

**Clinical Examination:**

Significant Findings:  
Extraoral:  
Intraoral:

**QUESTION # – (MORNING/AFTERNOON) SESSION**



(Select **ONE OR MORE** correct answers.)  
Which of the following is/are present?

- A. No evidence of bony fracture.
- B. Subcondylar fracture.
- C. Mandibular angle fracture.
- D. Mandibular body fracture.
- E. Mandibular parasymphiseal fracture.
- F. Alveolar fracture.
- G. Fractured tooth/teeth.
- H. Displaced tooth/teeth.
- I. Soft tissue injury.

## QUESTION # – (MORNING/AFTERNOON) SESSION

*Using the case history and the images, answer the following question on the answer sheet.*

**Patient Information:**

Age:		Blood Pressure:	/ mmHg
Gender:		Heart Rate:	bpm
Height:	cm	Respiration Rate:	/min
Weight:	kg	Temperature:	°C

**Chief Complaint:**

**History of Chief Complaint:**

**Dental History:**

**Medical History:**

Significant Findings:  
Current Medication:  
Allergies:


**Social/Family History:**

Significant Findings:

**Clinical Examination:**

Significant Findings:  
Extraoral:  
Intraoral:

## QUESTION # – (MORNING/AFTERNOON) SESSION



(Select **ONE OR MORE** correct answers.)

In addition to palpation, which of the following is/are indicated to establish a diagnosis of the swelling for this patient?

- A. Radiographic examination.
- B. Pulp vitality testing.
- C. Periodontal probing.
- D. Tooth percussion.
- E. Assessment of tooth mobility.
- F. Blood test analysis.
- G. Aspiration.
- H. Allergy testing.
- I. Biopsy.

## QUESTION # – (MORNING/AFTERNOON) SESSION

*Using the case history and the image, answer the following question on the answer sheet.*

**Patient Information:**

Age:		Blood Pressure:	/ mmHg
Gender:		Heart Rate:	bpm
Height:	cm	Respiration Rate:	/min
Weight:	kg	Temperature:	°C

**Chief Complaint:**

**History of Chief Complaint:**

**Dental History:**

**Medical History:**

Significant Findings:  
Current Medication:  
Allergies:

**Social/Family History:**

Significant Findings:

**Clinical Examination:**

Significant Findings:  
Extraoral:  
Intraoral:



**QUESTION # – (MORNING/AFTERNOON) SESSION**



(Select **ONE** correct answer.)

Which of the following is the most likely diagnosis of the swelling(s) seen on this patient?

- A. Hematoma.
- B. Edema.
- C. Subcutaneous emphysema.
- D. Neoplasm.
- E. Odontogenic infection.
- F. Nonodontogenic infection.
- G. Mucous retention phenomenon.
- H. Sialadenitis.
- I. Allergic reaction.
- J. Cyst.
- K. Muscle hypertrophy.
- L. Exostosis.
- M. Soft tissue hyperplasia.

## QUESTION # – (MORNING/AFTERNOON) SESSION

Using the case history and the image, answer the following question on the answer sheet.

### Patient Information:

Age:		Blood Pressure:	/ mmHg
Gender:		Heart Rate:	bpm
Height:	cm	Respiration Rate:	/min
Weight:	kg	Temperature:	°C

### Chief Complaint:

### History of Chief Complaint:

### Dental History:

### Medical History:

Significant Findings:  
Current Medication:  
Allergies:


### Social/Family History:

Significant Findings:

### Clinical Examination:

Significant Findings:  
Extraoral:  
Intraoral:

**QUESTION # – (MORNING/AFTERNOON) SESSION**



(Select **ONE OR MORE** correct answers.)

Which of the following is/are appropriate initial management(s) for this patient?

- A. No treatment.
- B. Periodontal debridement.
- C. Drainage through tooth/pulpectomy.
- D. Intraoral incision and drainage.
- E. Extraoral incision and drainage.
- F. Excision.
- G. Extraction.
- H. Antibiotic therapy.
- I. Administration of diphenhydramine.
- J. Administration of epinephrine.
- K. Appropriate referral.

## QUESTION # – (MORNING/AFTERNOON) SESSION

Using the case history and the image, answer the following question on the answer sheet.

**Patient Information:**

Age:		Blood Pressure:	/ mmHg
Gender:		Heart Rate:	bpm
Height:	cm	Respiration Rate:	/min
Weight:	kg	Temperature:	°C

**Chief Complaint:**

**History of Chief Complaint:**

**Dental History:**

**Medical History:**

Significant Findings:  
Current Medication:  
Allergies:

**Social/Family History:**

Significant Findings:

**Clinical Examination:**

Significant Findings:  
Extraoral:  
Intraoral:

**QUESTION # – (MORNING/AFTERNOON) SESSION**



(Select **ONE** correct answer.)

Which of the following is the most likely diagnosis of the swelling(s) seen on this patient?

- A. Hematoma.
- B. Edema.
- C. Neoplasm.
- D. Odontogenic infection.
- E. Nonodontogenic infection.
- F. Maxillary sinus retention cyst/antral pseudocyst.
- G. Sialadenitis/sialolith.
- H. Allergic reaction.
- I. Cyst.
- J. Muscle hypertrophy.
- K. Soft tissue hyperplasia.

## QUESTION # – (MORNING/AFTERNOON) SESSION

Using the case history and the image, answer the following question on the answer sheet.

### Patient Information:

Age:		Blood Pressure:	/ mmHg
Gender:		Heart Rate:	bpm
Height:	cm	Respiration Rate:	/min
Weight:	kg	Temperature:	°C

### Chief Complaint:

### History of Chief Complaint:

### Dental History:

### Medical History:

Significant Findings:  
Current Medication:  
Allergies:


### Social/Family History:

Significant Findings:

### Clinical Examination:

Significant Findings:  
Extraoral:  
Intraoral:

**QUESTION # – (MORNING/AFTERNOON) SESSION**



(Select **ONE OR MORE** correct answers.)

Which of the following is/are indicated to establish a diagnosis of this patient's pain?

- A. Radiographic examination.
- B. Pulp vitality testing.
- C. Periodontal probing.
- D. Tooth percussion.
- E. Application of pressure on individual cusps.
- F. Assessment of tooth mobility.
- G. Palpation.
- H. Evaluation of occlusion.
- I. Evaluation of restoration(s).
- J. Selective local anesthesia.
- K. Evaluation of lymph nodes.
- L. Microbiological testing.
- M. Cytological smear.
- N. Biopsy.
- O. Aspiration.

## QUESTION # – (MORNING/AFTERNOON) SESSION

*Using the case history and the image, answer the following question on the answer sheet.*

**Patient Information:**

Age:		Blood Pressure:	/ mmHg
Gender:		Heart Rate:	bpm
Height:	cm	Respiration Rate:	/min
Weight:	kg	Temperature:	°C

**Chief Complaint:**

**History of Chief Complaint:**

**Dental History:**

**Medical History:**

Significant Findings:  
Current Medication:  
Allergies:

**Social/Family History:**


Significant Findings:

**Clinical Examination:**

Significant Findings:  
Extraoral:  
Intraoral:



**QUESTION # – (MORNING/AFTERNOON) SESSION**



(Select **ONE OR MORE** correct answers.)

Which of the following is/are appropriate to manage this patient's pain?

- A. Analgesics.
- B. Antibiotic therapy.
- C. Extraction.
- D. Caries removal.
- E. Placement of sedative dressing.
- F. Placement of permanent restoration.
- G. Endodontic treatment.
- H. Periodontal treatment.
- I. Root desensitization.
- J. Incision and drainage.
- K. Occlusal adjustment.
- L. Fabrication of bite plane/night guard.
- M. Irrigation.
- N. Application of heat.
- O. Application of cold.

## QUESTION # – (MORNING/AFTERNOON) SESSION

*Using the case history and the image, answer the following question on the answer sheet.*

**Patient Information:**

Age:		Blood Pressure:	/ mmHg
Gender:		Heart Rate:	bpm
Height:	cm	Respiration Rate:	/min
Weight:	kg	Temperature:	°C

**Chief Complaint:**

**History of Chief Complaint:**

**Dental History:**

**Medical History:**

Significant Findings:  
Current Medication:  
Allergies:


**Social/Family History:**

Significant Findings:

**Clinical Examination:**

Significant Findings:  
Extraoral:  
Intraoral:

**QUESTION # – (MORNING/AFTERNOON) SESSION**



(Select **ONE OR MORE** correct answers.)

Which of the following is/are appropriate to manage this patient?

- A. Analgesics.
- B. Antibiotic therapy.
- C. Antiviral therapy.
- D. Antifungal therapy.
- E. Placement of sedative dressing.
- F. Irrigation.
- G. Topical corticosteroids.

## QUESTION # – (MORNING/AFTERNOON) SESSION

*Using the case history and the images, answer the following question on the answer sheet.*

**Patient Information:**

Age:		Blood Pressure:	/ mmHg
Gender:		Heart Rate:	bpm
Height:	cm	Respiration Rate:	/min
Weight:	kg	Temperature:	°C

**Chief Complaint:**

**History of Chief Complaint:**

**Dental History:**

**Medical History:**

Significant Findings:  
Current Medication:  
Allergies:


**Social/Family History:**

Significant Findings:

**Clinical Examination:**

Significant Findings:  
Extraoral:  
Intraoral:

**QUESTION # – (MORNING/AFTERNOON) SESSION**



(Select **ONE** correct answer.)

What is the most likely reason for this patient's pain?

- A. Pericoronitis.
- B. Alveolar osteitis.
- C. Asymptomatic irreversible pulpitis.
- D. Symptomatic irreversible pulpitis.
- E. Reversible pulpitis.
- F. Periodontal abscess.
- G. Acute apical abscess.
- H. Chronic apical abscess.
- I. Tooth fracture.
- J. Trigeminal neuralgia/atypical facial pain.
- K. Necrotizing ulcerative gingivitis/periodontitis.
- L. Dentinal hypersensitivity.
- M. Impacted tooth.
- N. Occlusal trauma.
- O. Maxillary sinusitis.

## QUESTION # – (MORNING/AFTERNOON) SESSION

*Using the case history, charting and the images, answer the following question on the answer sheet.*

**Patient Information:**

Age:		Blood Pressure:	/ mmHg
Gender:		Heart Rate:	bpm
Height:	cm	Respiration Rate:	/min
Weight:	kg	Temperature:	°C

**Chief Complaint:**

**History of Chief Complaint:**

**Dental History:**

**Medical History:**

Significant Findings:  
Current Medication:  
Allergies:


**Social/Family History:**

Significant Findings:

**Clinical Examination:**

Significant Findings:  
Extraoral:  
Intraoral:

**QUESTION # – (MORNING/AFTERNOON) SESSION**



**Vestibular**

<b>Tooth</b>					
<b>Probing depth</b>					
<b>Recession</b>					
<b>Bleeding on probing</b>					

**Lingual**

<b>Tooth</b>					
<b>Probing depth</b>					
<b>Recession</b>					
<b>Bleeding on probing</b>					

<b>Mobility</b>					
<b>Furcation</b>					

(Select **ONE OR MORE** correct answers.)

Which of the following should be performed during the initial (Phase I) periodontal management of this patient?

- A. Periodontal debridement.
- B. Caries management.
- C. Oral hygiene instruction.
- D. Chlorhexidine mouth rinse therapy.
- E. Systemic antibiotic therapy.
- F. Extraction.
- G. Occlusal adjustment.
- H. Bite plane/mouth guard fabrication.
- I. Orthodontic tooth movement.
- J. Replacement of defective restoration(s)/removal of overhang(s).
- K. Denture adjustment/modification.
- L. Periodontal flap surgery.
- M. Gingival graft(s).
- N. Root canal therapy.
- O. Splinting.

## QUESTION # – (MORNING/AFTERNOON) SESSION

*Using the case history, charting and the images, answer the following question on the answer sheet.*

**Patient Information:**

Age:		Blood Pressure:	/ mmHg
Gender:		Heart Rate:	bpm
Height:	cm	Respiration Rate:	/min
Weight:	kg	Temperature:	°C

**Chief Complaint:**

**History of Chief Complaint:**

**Dental History:**

**Medical History:**

Significant Findings:  
Current Medication:  
Allergies:

**Social/Family History:**




Significant Findings:

**Clinical Examination:**

Significant Findings:  
Extraoral:  
Intraoral:



**QUESTION # – (MORNING/AFTERNOON) SESSION**



**Vestibular**

<b>Tooth</b>					
<b>Probing depth</b>					
<b>Recession</b>					
<b>Bleeding on probing</b>					

**Lingual**

<b>Tooth</b>					
<b>Probing depth</b>					
<b>Recession</b>					
<b>Bleeding on probing</b>					

<b>Mobility</b>					
<b>Furcation</b>					

(Select **ONE** correct answer.)

Which periodontal surgical procedure is most appropriate for this patient?

- A. Open flap debridement alone.
- B. Open flap debridement with apically positioned flap.
- C. Coronally positioned flap.
- D. Laterally positioned flap.
- E. Free autogenous gingival graft.
- F. Subepithelial connective tissue graft.
- G. Guided tissue regeneration.
- H. Bone graft.
- I. Crown lengthening.
- J. Gingivectomy/gingivoplasty.
- K. Frenectomy/frenotomy.
- L. Surgical tooth exposure.
- M. Distal wedge.
- N. Gingival curettage.
- O. Root amputation/hemisection.

## QUESTION # – (MORNING/AFTERNOON) SESSION

*Using the case history, charting and the images, answer the following question on the answer sheet.*

**Patient Information:**

Age:		Blood Pressure:	/ mmHg
Gender:		Heart Rate:	bpm
Height:	cm	Respiration Rate:	/min
Weight:	kg	Temperature:	°C

**Chief Complaint:**

**History of Chief Complaint:**

**Dental History:**

**Medical History:**

Significant Findings:  
Current Medication:  
Allergies:




**Social/Family History:**

Significant Findings:

**Clinical Examination:**

Significant Findings:  
Extraoral:  
Intraoral:

**QUESTION # – (MORNING/AFTERNOON) SESSION**



**Vestibular**

<b>Tooth</b>					
<b>Probing depth</b>					
<b>Recession</b>					
<b>Bleeding on probing</b>					

**Lingual**

<b>Tooth</b>					
<b>Probing depth</b>					
<b>Recession</b>					
<b>Bleeding on probing</b>					

<b>Mobility</b>					
<b>Furcation</b>					


(Select **ONE OR MORE** correct answers.)

Which of the following contribute(s) to this patient's periodontal status?

- A. Calculus and/or bacterial plaque.
- B. Root morphology and/or furcation involvement.
- C. Denture-induced trauma.
- D. Toothbrush-induced trauma.
- E. Developmental tooth anomaly.
- F. Inadequate interproximal contact(s)/food impaction.
- G. Deficient restoration(s) and/or inadequate embrasure space.
- H. Systemic factors.
- I. Periodontal pocket(s).
- J. Patient medication(s).
- K. Tobacco use.
- L. Combined endodontic-periodontic lesion.
- M. Occlusal trauma.
- N. Root fracture or perforation.
- O. Lack of patient compliance.

## QUESTION # – (MORNING/AFTERNOON) SESSION

Using the image, answer the following question on the answer sheet.




(Select **ONE OR MORE** correct answers.)

There is radiographic evidence of **caries** on the

- A. distal of tooth \_\_\_.
- B. mesial of tooth \_\_\_.
- C. distal of tooth \_\_\_.
- D. mesial of tooth \_\_\_.
- E. distal of tooth \_\_\_.
- F. mesial of tooth \_\_\_.
- G. distal of tooth \_\_\_.
- H. mesial of tooth \_\_\_.
- I. distal of tooth \_\_\_.
- J. mesial of tooth \_\_\_.
- K. distal of tooth \_\_\_.

## QUESTION # – (MORNING/AFTERNOON) SESSION

Using the image, answer the following question on the answer sheet.




(Select **ONE OR MORE** correct answers.)

There is radiographic evidence of **calculus** on the

- A. distal of tooth \_\_\_.
- B. mesial of tooth \_\_\_.
- C. distal of tooth \_\_\_.
- D. mesial of tooth \_\_\_.
- E. distal of tooth \_\_\_.
- F. mesial of tooth \_\_\_.
- G. distal of tooth \_\_\_.
- H. mesial of tooth \_\_\_.
- I. distal of tooth \_\_\_.
- J. mesial of tooth \_\_\_.
- K. distal of tooth \_\_\_.

## QUESTION # – (MORNING/AFTERNOON) SESSION

Using the image, answer the following question on the answer sheet.




(Select **ONE OR MORE** correct answers.)

There is radiographic evidence of a **defective restoration** on the

- A. distal of tooth \_\_\_.
- B. mesial of tooth \_\_\_.
- C. distal of tooth \_\_\_.
- D. mesial of tooth \_\_\_.
- E. distal of tooth \_\_\_.
- F. mesial of tooth \_\_\_.
- G. distal of tooth \_\_\_.
- H. mesial of tooth \_\_\_.
- I. distal of tooth \_\_\_.
- J. mesial of tooth \_\_\_.
- K. distal of tooth \_\_\_.
- L. none of the above.

## QUESTION # – (MORNING/AFTERNOON) SESSION

Using the image, answer the following question on the answer sheet.




(Select **ONE OR MORE** correct answers.)

There is radiographic evidence of **caries** on the

- A. distal of tooth \_\_\_.
- B. mesial of tooth \_\_\_.
- C. distal of tooth \_\_\_.
- D. mesial of tooth \_\_\_.
- E. distal of tooth \_\_\_.
- F. mesial of tooth \_\_\_.
- G. distal of tooth \_\_\_.
- H. mesial of tooth \_\_\_.
- I. distal of tooth \_\_\_.
- J. mesial of tooth \_\_\_.
- K. distal of tooth \_\_\_.
- L. none of the above.

## QUESTION # – (MORNING/AFTERNOON) SESSION

Using the image, answer the following question on the answer sheet.



(Select **ONE OR MORE** correct answers.)


There is radiographic evidence of **calculus** on the

- A. distal of tooth \_\_\_.
- B. mesial of tooth \_\_\_.
- C. distal of tooth \_\_\_.
- D. mesial of tooth \_\_\_.
- E. distal of tooth \_\_\_.
- F. mesial of tooth \_\_\_.
- G. distal of tooth \_\_\_.
- H. mesial of tooth \_\_\_.
- I. distal of tooth \_\_\_.
- J. mesial of tooth \_\_\_.
- K. distal of tooth \_\_\_.
- L. none of the above.



## QUESTION # – (MORNING/AFTERNOON) SESSION

Using the image, answer the following question on the answer sheet.



(Select **ONE OR MORE** correct answers.)

There is radiographic evidence of a **defective restoration** on the

- A. distal of tooth \_\_\_.
- B. mesial of tooth \_\_\_.
- C. distal of tooth \_\_\_.
- D. mesial of tooth \_\_\_.
- E. distal of tooth \_\_\_.
- F. mesial of tooth \_\_\_.
- G. distal of tooth \_\_\_.
- H. mesial of tooth \_\_\_.
- I. distal of tooth \_\_\_.
- J. mesial of tooth \_\_\_.
- K. distal of tooth \_\_\_.
- L. none of the above.

## QUESTION # – (MORNING/AFTERNOON) SESSION

Using the case history and the image, answer the following question on the answer sheet.

**Patient Information:**

Age:		Blood Pressure:	/ mmHg
Gender:		Heart Rate:	bpm
Height:	cm	Respiration Rate:	/min
Weight:	kg	Temperature:	°C

**Chief Complaint:**

**History of Chief Complaint:**

**Dental History:**

**Medical History:**

Significant Findings:  
Current Medication:  
Allergies:


**Social/Family History:**

Significant Findings:

**Clinical Examination:**

Significant Findings:  
Extraoral:  
Intraoral:

**QUESTION # – (MORNING/AFTERNOON) SESSION**



(Select **ONE OR MORE** correct answers.)

Which of the following is/are visible on the image?

- A. Caries.
- B. Calculus.
- C. Defective restoration.
- D. Foreign body.
- E. Periodontal bone loss.
- F. Root resorption.
- G. Retained primary tooth.
- H. Root fragment.
- I. Rarefying osteitis.
- J. Sclerosing osteitis/condensing osteitis.
- K. Attrition/abrasion.
- L. Hypercementosis.
- M. Root fracture.
- N. None of the above.

## QUESTION # – (MORNING/AFTERNOON) SESSION

*Using the case history and the images, answer the following question on the answer sheet.*

**Patient Information:**

Age:		Blood Pressure:	/ mmHg
Gender:		Heart Rate:	bpm
Height:	cm	Respiration Rate:	/min
Weight:	kg	Temperature:	°C

**Chief Complaint:**

**History of Chief Complaint:**

**Dental History:**

**Medical History:**

Significant Findings:  
Current Medication:  
Allergies:


**Social/Family History:**

Significant Findings:

**Clinical Examination:**

Significant Findings:  
Extraoral:  
Intraoral:

**QUESTION # – (MORNING/AFTERNOON) SESSION**



(Select **ONE OR MORE** correct answers.)

Which of the following is/are evident on the image(s)?

- A. Ectopic eruption.
- B. Impacted tooth/teeth.
- C. Gemination.
- D. Fusion.
- E. Space loss.
- F. Dens invaginatus/dens-in-dente.
- G. Dens evaginatus.
- H. Arrested root development.
- I. Dilaceration.
- J. Congenital absence of permanent tooth/teeth.
- K. Ankylosis.
- L. Retained root(s).
- M. Foreign body.
- N. Supernumerary tooth/teeth.
- O. Dentigerous cyst.

## QUESTION # – (MORNING/AFTERNOON) SESSION

Using the image, answer the following question on the answer sheet.



(Select **ONE OR MORE** correct answers.)

Which of the following is/are radiographically evident on tooth \_\_\_\_ and/or tooth \_\_\_\_?

- A. Occlusal caries.
- B. Mesial caries.
- C. Distal caries.
- D. Root caries.
- E. Cervical burnout.
- F. Physiologic root resorption.
- G. Internal root resorption.
- H. External root resorption.
- I. Fractured tooth/teeth.
- J. Furcation radiolucency.
- K. Periapical radiolucency.
- L. Pulpal obliteration.
- M. Calculus.
- N. Attrition.
- O. A defective or inadequate restoration.

## QUESTION # – (MORNING/AFTERNOON) SESSION

*Using the case history and the images, answer the following question on the answer sheet.*

**Patient Information:**

Age:		Blood Pressure:	/ mmHg
Gender:		Heart Rate:	bpm
Height:	cm	Respiration Rate:	/min
Weight:	kg	Temperature:	°C

**Chief Complaint:**

**History of Chief Complaint:**

**Dental History:**

**Medical History:**

Significant Findings:  
Current Medication:  
Allergies:



**Social/Family History:**

Significant Findings:

**Clinical Examination:**

Significant Findings:  
Extraoral:  
Intraoral:

**QUESTION # – (MORNING/AFTERNOON) SESSION**



(Select **ONE OR MORE** correct answers.)

What is/are appropriate management(s) for tooth \_\_\_?

- A. Observation only.
- B. Reassessment in 3-6 months.
- C. Remineralization.
- D. A pit and fissure sealant.
- E. A direct restoration.
- F. Stainless steel crown.
- G. An indirect pulp cap.
- H. A partial pulpotomy.
- I. A pulpotomy.
- J. A pulpectomy.
- K. Extraction without space maintainer.
- L. Extraction with space maintainer.
- M. Prescribe an analgesic.
- N. Prescribe an antibiotic.



## QUESTION # – (MORNING/AFTERNOON) SESSION

*Using the case history and the image, answer the following question on the answer sheet.*

**Patient Information:**

Age:		Blood Pressure:	/ mmHg
Gender:		Heart Rate:	bpm
Height:	cm	Respiration Rate:	/min
Weight:	kg	Temperature:	°C

**Chief Complaint:**

**History of Chief Complaint:**

**Dental History:**

**Medical History:**

Significant Findings:  
Current Medication:  
Allergies:


**Social/Family History:**

Significant Findings:

**Clinical Examination:**

Significant Findings:  
Extraoral:  
Intraoral:

**QUESTION # – (MORNING/AFTERNOON) SESSION**



(Select **ONE OR MORE** correct answers.)

What is/are appropriate immediate management(s) for the patient?

- A. Observation only.
- B. Direct restoration.
- C. Direct pulp cap.
- D. Partial pulpotomy.
- E. Pulpotomy.
- F. Pulpectomy.
- G. Extraction.
- H. Reposition and splint.
- I. Approximation of the tooth fragment(s).
- J. Tetanus prophylaxis.
- K. Antibiotic therapy.

## QUESTION # – (MORNING/AFTERNOON) SESSION

Using the case history and the image, answer the following question on the answer sheet.

### Patient Information:

Age:		Blood Pressure:	/ mmHg
Gender:		Heart Rate:	bpm
Height:	cm	Respiration Rate:	/min
Weight:	kg	Temperature:	°C

### Chief Complaint:

### History of Chief Complaint:

### Dental History:

### Medical History:

Significant Findings:  
Current Medication:  
Allergies:

### Social/Family History:

Significant Findings:

### Clinical Examination:

Significant Findings:  
Extraoral:  
Intraoral:

**QUESTION # – (MORNING/AFTERNOON) SESSION**




(Select **ONE OR MORE** correct answers.)

Which of the following is/are seen in the image of this child?

- A. No abnormalities.
- B. Early childhood caries.
- C. Caries.
- D. Enamel hypoplasia.
- E. Dentinogenesis imperfecta.
- F. Amelogenesis imperfecta.
- G. Discoloured tooth/teeth.
- H. Attrition.
- I. Supernumerary tooth/teeth.
- J. Ectopic eruption.
- K. Retained primary tooth.
- L. Transposition.
- M. Pulp polyp.
- N. Eruption cyst.
- O. Cheek/lip biting injury.

## QUESTION # – (MORNING/AFTERNOON) SESSION

Using the image, answer the following question on the answer sheet.



(Select **ONE OR MORE** correct answers.)

The space management appliance is

- A. acceptable.
- B. inadequate in the adaptation of the band(s).
- C. incorrect in the positioning of the band(s).
- D. inappropriate for the clinical situation.
- E. an inappropriate appliance design.
- F. incorrect in the position of the wire buccally.
- G. incorrect in the position of the wire lingually.
- H. incorrect in the position of the wire occlusally.
- I. incorrect in the position of the wire gingivally.
- J. incorrect in the position of the wire anteriorly.
- K. incorrect in the position of the wire posteriorly.
- L. unacceptable at the solder joint(s).

## QUESTION # – (MORNING/AFTERNOON) SESSION

*Using the case history and the images, answer the following question on the answer sheet.*

**Patient Information:**

Age:		Blood Pressure:	/ mmHg
Gender:		Heart Rate:	bpm
Height:	cm	Respiration Rate:	/min
Weight:	kg	Temperature:	°C

**Chief Complaint:**

**History of Chief Complaint:**

**Dental History:**

**Medical History:**

Significant Findings:  
Current Medication:  
Allergies:


**Social/Family History:**

Significant Findings:

**Clinical Examination:**

Significant Findings:  
Extraoral:  
Intraoral:

## QUESTION # – (MORNING/AFTERNOON) SESSION




(Select **ONE OR MORE** correct answers.)

Appropriate space management for this case is

- A. observation only.
- B. reassessment in 3 - 6 months.
- C. interproximal discing.
- D. separators.
- E. a distalizing appliance.
- F. a band and loop appliance.
- G. a distal shoe appliance.
- H. a mandibular lingual arch.
- I. a fixed palatal arch with an anterior button (a Nance appliance).
- J. a habit breaking appliance.
- K. extraction.

## QUESTION # – (MORNING/AFTERNOON) SESSION

*The diagram is a cross-section through the mandible at the level of the lingula. The needle is being inserted for an injection of a standard inferior alveolar nerve block. Answer the following question on the answer sheet.*



(Select **TWO** correct answers.)

The anatomical structures labelled "\_\_\_\_" and "\_\_\_\_" are the

- A. facial nerve.
- B. lingual nerve.
- C. long buccal nerve.
- D. inferior alveolar nerve.
- E. inferior alveolar artery.
- F. inferior alveolar vein.
- G. masseter muscle.
- H. medial pterygoid muscle.
- I. buccinator muscle.
- J. tendon of temporalis.
- K. sphenomandibular ligament.
- L. pterygomandibular raphe.
- M. pterygomandibular space.
- N. external oblique ridge.
- O. parotid gland.



## QUESTION # – (MORNING/AFTERNOON) SESSION

*The diagram is a cross-section through the mandible at the level of the lingula. The needle is being inserted for an injection of a standard inferior alveolar nerve block. Answer the following question on the answer sheet.*



(Select **ONE OR MORE** correct answers.)

Injection of \_\_\_\_\_ into the structure "\_\_\_\_" could result in

- A. trismus.
- B. hematoma.
- C. paresthesia.
- D. pain.
- E. seizure.
- F. tachycardia.
- G. facial nerve paralysis.
- H. broken needle.
- I. failed anesthesia.
- J. successful anesthesia without complication.

## QUESTION # – (MORNING/AFTERNOON) SESSION

Using the case synopsis and the images, answer the following question on the answer sheet.

### CASE SYNOPSIS

*Brief synopsis of the situation:*


(Select **ONE OR MORE** correct answers.)

Which of the following images illustrate(s) the final needle position (point of insertion, angulation, and depth) immediately prior to injection that will best accomplish complete local anesthesia for this procedure? A \_\_\_\_\_ needle is being used. Assume that anesthesia is **NOT** required for rubber dam clamp placement.


A.



B.




C.




D.




E.




F.



G.



H.



## QUESTION # – (MORNING/AFTERNOON) SESSION









Using the case synopsis and the images, answer the following question on the answer sheet.

### CASE SYNOPSIS

*Brief synopsis of situation:*

(Select **ONE OR MORE** correct answers.)

Which of the following images illustrate(s) the final needle position (point of insertion, angulation, and depth) immediately prior to injection that will best accomplish complete local anesthesia for this procedure? A \_\_\_\_\_ needle is being used.

A.		B.	
C.		D.	
E.		F.	
G.		H.	

## QUESTION # – (MORNING/AFTERNOON) SESSION

Using the case synopsis and the images, answer the following question on the answer sheet.









### CASE SYNOPSIS

*Brief synopsis of the situation.*

(Select **ONE OR MORE** correct answers.)

Which of the following images illustrate(s) the correct final needle position (point of insertion, angulation, and depth) immediately prior to injection that will best accomplish local anesthesia for this procedure?

A \_\_\_\_\_ needle is being used. Assume that anesthesia is NOT required for rubber dam clamp placement.

A.		B.	
C.		D.	
E.		F.	
G.		H.	

## QUESTION # – (MORNING/AFTERNOON) SESSION

Using the case synopsis and the images, answer the following question on the answer sheet.









### CASE SYNOPSIS

*Brief synopsis of the situation.*

(Select **ONE OR MORE** correct answers.)

Which of the following images illustrate(s) the correct final needle position (point of insertion, angulation, and depth) immediately prior to injection that will best accomplish local anesthesia for this procedure?

A \_\_\_\_\_ needle is being used.

A.		B.	
C.		D.	
E.		F.	
G.		H.	

## QUESTION # – (MORNING/AFTERNOON) SESSION

Using the case synopsis and the images, answer the following question on the answer sheet.

### CASE SYNOPSIS

*Brief synopsis of the situation.*

(Select **ONE OR MORE** correct answers.)

Which of the following images illustrate(s) the correct final needle position immediately prior to injection that will best accomplish local anesthesia for this procedure?

A.	<input type="checkbox"/>	B.	<input type="checkbox"/>
C.	<input type="checkbox"/>	D.	<input type="checkbox"/>
E.	<input type="checkbox"/>	F.	<input type="checkbox"/>
G.	<input type="checkbox"/>	H.	<input type="checkbox"/>

## QUESTION # – (MORNING/AFTERNOON) SESSION

Using the case history, write a prescription for the most appropriate **ANTIBIOTIC** for this patient.

**PATIENT:** \_\_\_\_\_  
\_\_\_\_\_  
\_\_\_\_\_

**Patient Information:**

Age:		Blood Pressure:	/ mmHg
Gender:		Heart Rate:	bpm
Height:	cm	Respiration Rate:	/min
Weight:	kg	Temperature:	°C

**Chief Complaint:**

**History of Chief Complaint:**

**Dental History:**

**Medical History:**

Significant Findings:  
Current Medication:  
Allergies:

**Social/Family History:**

Significant Findings:

**Clinical Examination:**

Significant Findings:  
Extraoral:  
Intraoral:

**Write a prescription for the most appropriate ANTIBIOTIC for this patient. If a drug trade name is used, the prescription must include the generic name.**

**QUESTION # – (MORNING/AFTERNOON) SESSION**

(Value 4)

**NDEB ID#** \_\_\_\_\_

**DOCTOR XXX XXXXX  
100 ANYWHERE STREET  
ANYWHERE CITY, CANADA**

DATE: \_\_\_\_\_

NAME: \_\_\_\_\_

ADDRESS: \_\_\_\_\_  
\_\_\_\_\_  
\_\_\_\_\_

**Rx**

NO REPEAT

REPEAT \_\_\_\_ TIME(S)

SIGNATURE XXXXXXXXXXXXXXXXXX  
**(DO NOT SIGN PRESCRIPTION)**



## QUESTION # – (MORNING/AFTERNOON) SESSION

Using the case history, write a prescription for the most appropriate **ANALGESIC** for this patient.

**PATIENT:** \_\_\_\_\_  
\_\_\_\_\_  
\_\_\_\_\_

**Patient Information:**

Age:		Blood Pressure:	/ mmHg
Gender:		Heart Rate:	bpm
Height:	cm	Respiration Rate:	/min
Weight:	kg	Temperature:	°C

**Chief Complaint:**

**History of Chief Complaint:**

**Dental History:**

**Medical History:**

Significant Findings:  
Current Medication:  
Allergies:

**Social/Family History:**

Significant Findings:

**Clinical Examination:**

Significant Findings:  
Extraoral:  
Intraoral:

**Write a prescription for the most appropriate ANALGESIC for this patient. If a drug trade name is used, the prescription must include the generic name.**

**QUESTION # – (MORNING/AFTERNOON) SESSION**

(Value 4)

**NDEB ID#** \_\_\_\_\_

**DOCTOR XXX XXXXX  
100 ANYWHERE STREET  
ANYWHERE CITY, CANADA**

DATE: \_\_\_\_\_

NAME: \_\_\_\_\_

ADDRESS: \_\_\_\_\_  
\_\_\_\_\_  
\_\_\_\_\_

**Rx**

NO REPEAT

REPEAT \_\_\_\_ TIME(S)

SIGNATURE XXXXXXXXXXXXXXXXXX  
(DO NOT SIGN PRESCRIPTION)

## QUESTION # – (MORNING/AFTERNOON) SESSION

Using the case history, write a prescription for the most appropriate drug for this patient.

**PATIENT:** \_\_\_\_\_  
\_\_\_\_\_  
\_\_\_\_\_

**Patient Information:**

Age:		Blood Pressure:	/ mmHg
Gender:		Heart Rate:	bpm
Height:	cm	Respiration Rate:	/min
Weight:	kg	Temperature:	°C

**Chief Complaint:**

**History of Chief Complaint:**

**Dental History:**

**Medical History:**

Significant Findings:  
Current Medication:  
Allergies:

**Social/Family History:**

Significant Findings:

**Clinical Examination:**

Significant Findings:  
Extraoral:  
Intraoral:

**Write a prescription for the most appropriate drug for this patient, using the generic name of the drug.**

**QUESTION # – (MORNING/AFTERNOON) SESSION**

(Value 4)

**NDEB ID#** \_\_\_\_\_

**DOCTOR XXX XXXXX  
100 ANYWHERE STREET  
ANYWHERE CITY, CANADA**

DATE: \_\_\_\_\_

NAME: \_\_\_\_\_

ADDRESS: \_\_\_\_\_  
\_\_\_\_\_  
\_\_\_\_\_

**Rx**

NO REPEAT

REPEAT \_\_\_\_ TIME(S)

SIGNATURE XXXXXXXXXXXXXXXXXX  
(DO NOT SIGN PRESCRIPTION)